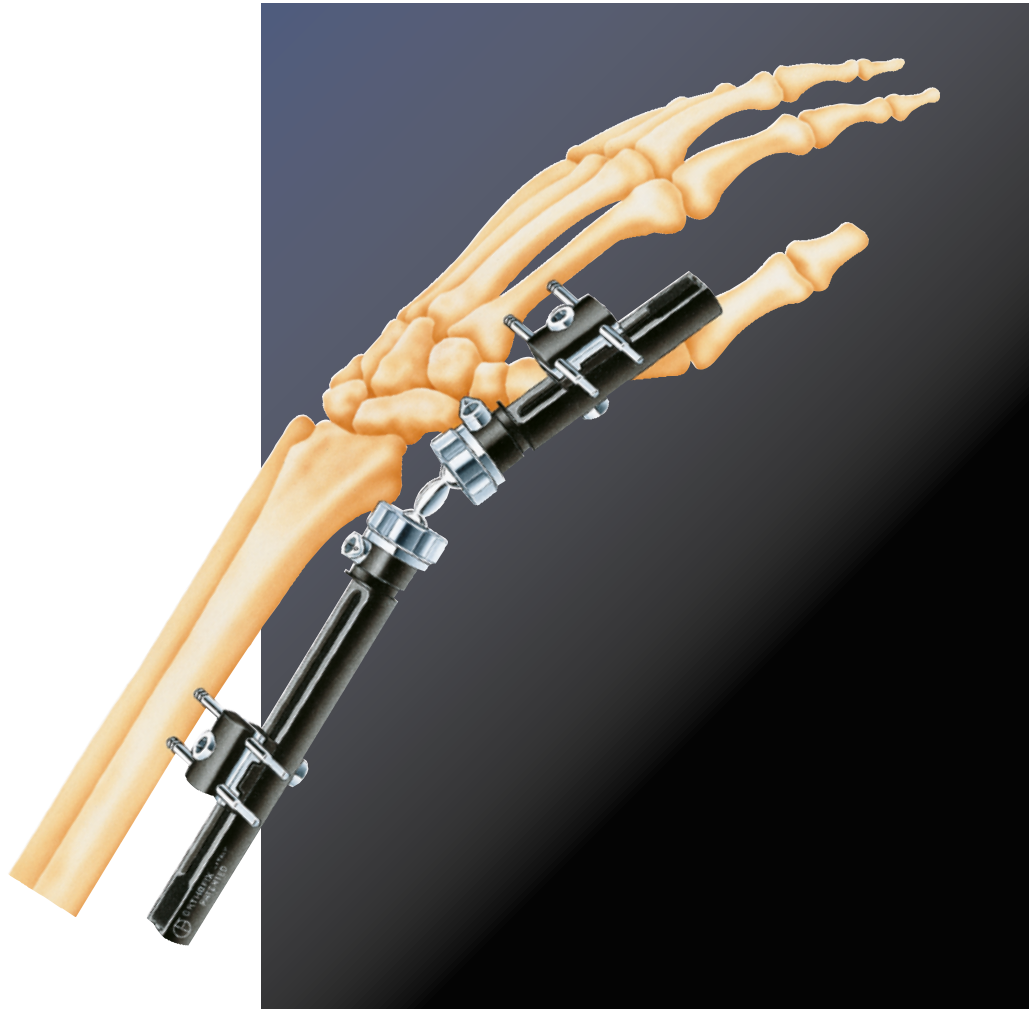

The Pennig Dynamic Wrist Fixator

Fractures of the Distal Radius and Radial Osteotomies

EXTRA-ARTICULAR APPLICATION

| | |
|---|---|
| Equipment Required | 1 |
| Additional Instrumentation..... | 1 |
| Re-assembly following Sterilization | 2 |
| Operative Technique | 4 |

TRANS-ARTICULAR APPLICATION

| | |
|---|----|
| Equipment Required | 11 |
| The Orthofix Fragment Fixation System | 11 |
| Additional Instrumentation..... | 11 |
| Re-assembly following Sterilization | 12 |
| Operative Technique | 13 |
| Reduction Techniques..... | 17 |
| Use of the Ulnar Outtrigger Clamp | 20 |

SUPPLEMENTARY TECHNIQUES

| | |
|--|----|
| Harvesting Bone Grafts..... | 21 |
| Limited Internal Fixation with the Orthofix Fragment Fixation System | 21 |
| Bone Screw Anchorage in Osteoporosis | 26 |
| Indications for the Use of the Smaller Screws..... | 26 |

CORRECTIVE OSTEOTOMIES OF THE DISTAL RADIUS

| | |
|---------------------------------------|----|
| Introduction | 27 |
| Objectives and Priorities..... | 27 |
| Planning the Operation | 27 |
| Loss of Dorsal Angulation..... | 28 |
| Correction of Dorsal Angulation | 28 |
| Equipment Required | 29 |
| Additional Instrumentation..... | 29 |
| Operative Technique | 30 |

| | |
|----------------------------------|----|
| REFERENCES AND BIBLIOGRAPHY..... | 38 |
|----------------------------------|----|

Please kindly refer to the product IFU PQWRI, to the Orthofix implantable devices and related instrument IFU PQSCR, and to the reusable medical devices IFU PQRMD that contain instructions for use of the product.

Operative Technique Contributing Surgeon:
Prof. Dr. D. Pennig

EQUIPMENT REQUIRED**Pennig Dynamic Wrist Fixator
for Extra-Articular Fractures (37002) consisting of:**

- 1 Compression-Distractor Module (37060)
- 1 Short Module with T-Clamp (37011)
- 1 Double Ball-Joint (37030)

or

- 1 Extra-Articular Radiolucent Wrist Clamp (37070)
- 1 Short Module (37010)
- 1 Double Ball-Joint (37030)

- 2 Template/Conversion Clamps (13710)

- 2 Screw Guides/ Templates with handles (13520)

- 1 Drill Guide 2.7mm diameter (13530)

- 1 Drill Bit Kit 2.7mm diameter (13550)

- 1 Tapered Trocar (13540)

- 1 T-Wrench for Clamp Screws (13570)

- 1 T-Wrench for Bone Screws (M210)

- 2 Pilot Wire Guides (13532)
for 1.5-1.6mm Kirschner Wires

- 3 Cortical Screws 70/20,
3.0-3.3mm thread diameter (35100)

- 1 Cortical Screw 80/35,
3.0-3.3mm thread diameter (35101)

**ADDITIONAL INSTRUMENTATION
(not provided)**

- 2 Langenbeck Retractors-Small

- Adson Forceps

- Scalpels (Nos. 11 & 15)

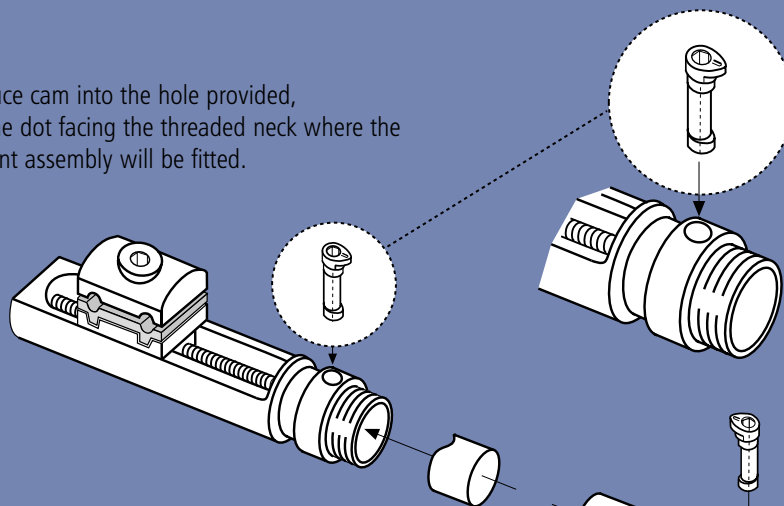
- Small Scissors

- Air Drill

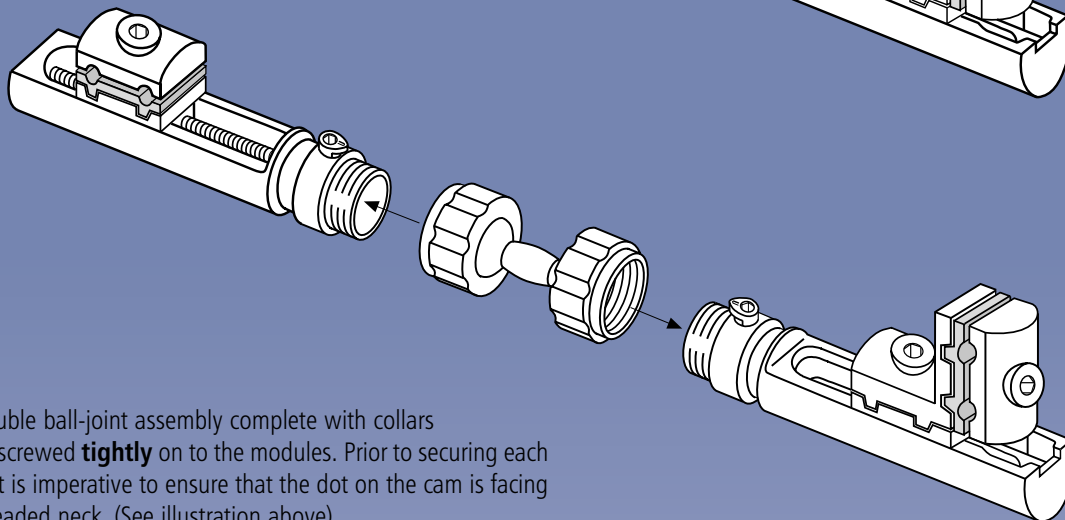
- 2 Kirschner Wires 1.5mm or 1.6mm

RE-ASSEMBLY FOLLOWING STERILIZATION

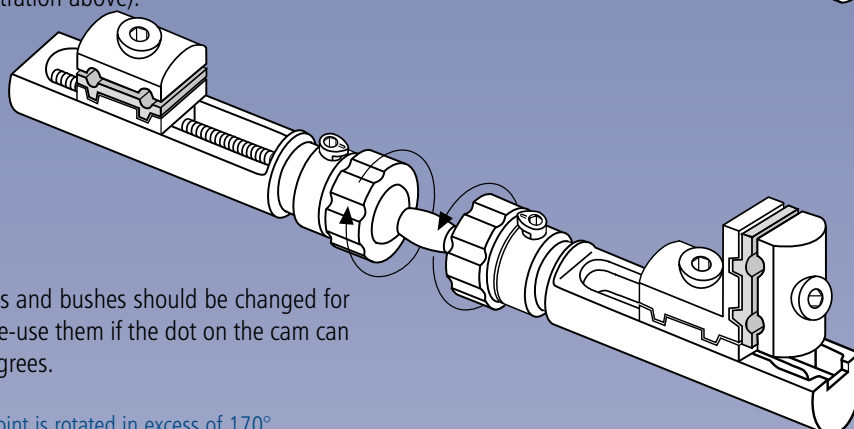
1. Introduce cam into the hole provided, with the dot facing the threaded neck where the ball-joint assembly will be fitted.



2. Align the groove on the bush with the long axis of the cam and seat components within the recess.



3. The double ball-joint assembly complete with collars is now screwed **tightly** on to the modules. Prior to securing each collar, it is imperative to ensure that the dot on the cam is facing the threaded neck. (See illustration above).



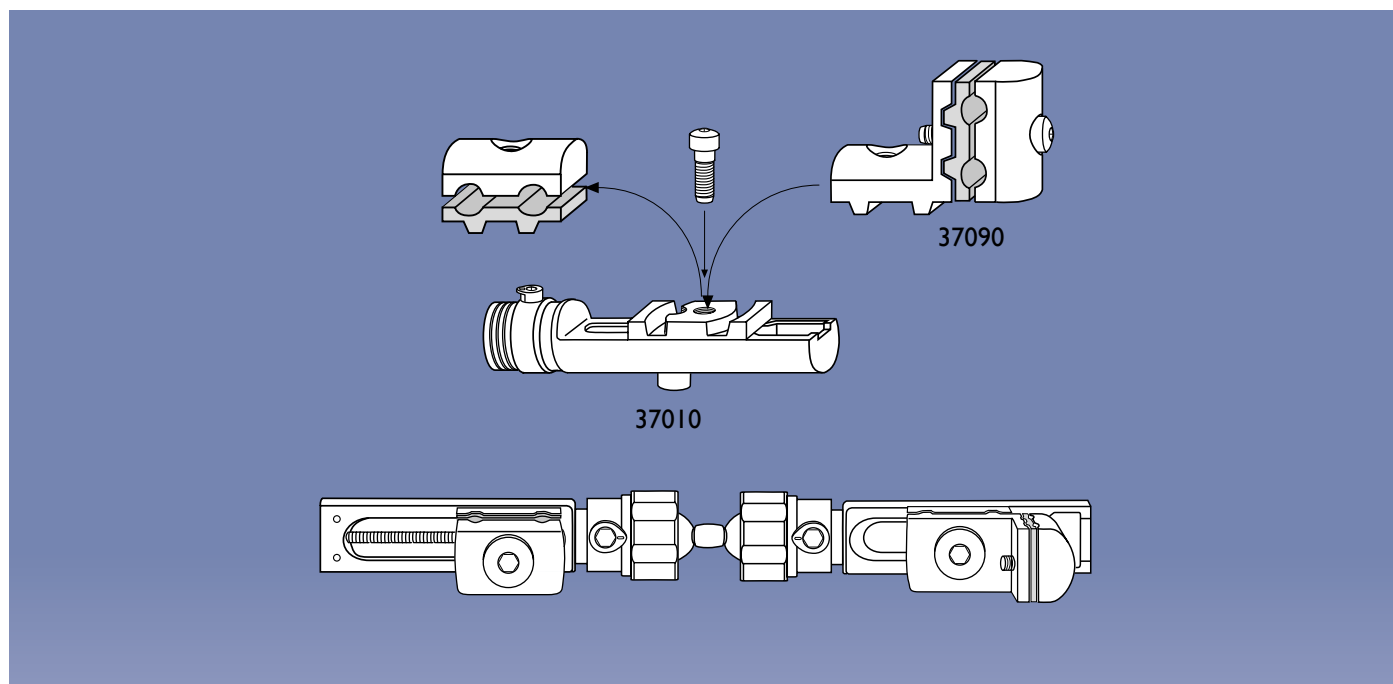
If the fixator is reused, the cams and bushes should be changed for each new application. Do not re-use them if the dot on the cam can be rotated in excess of 170 degrees.



WARNING: If the ball-joint is rotated in excess of 170° degrees, it may become loose.

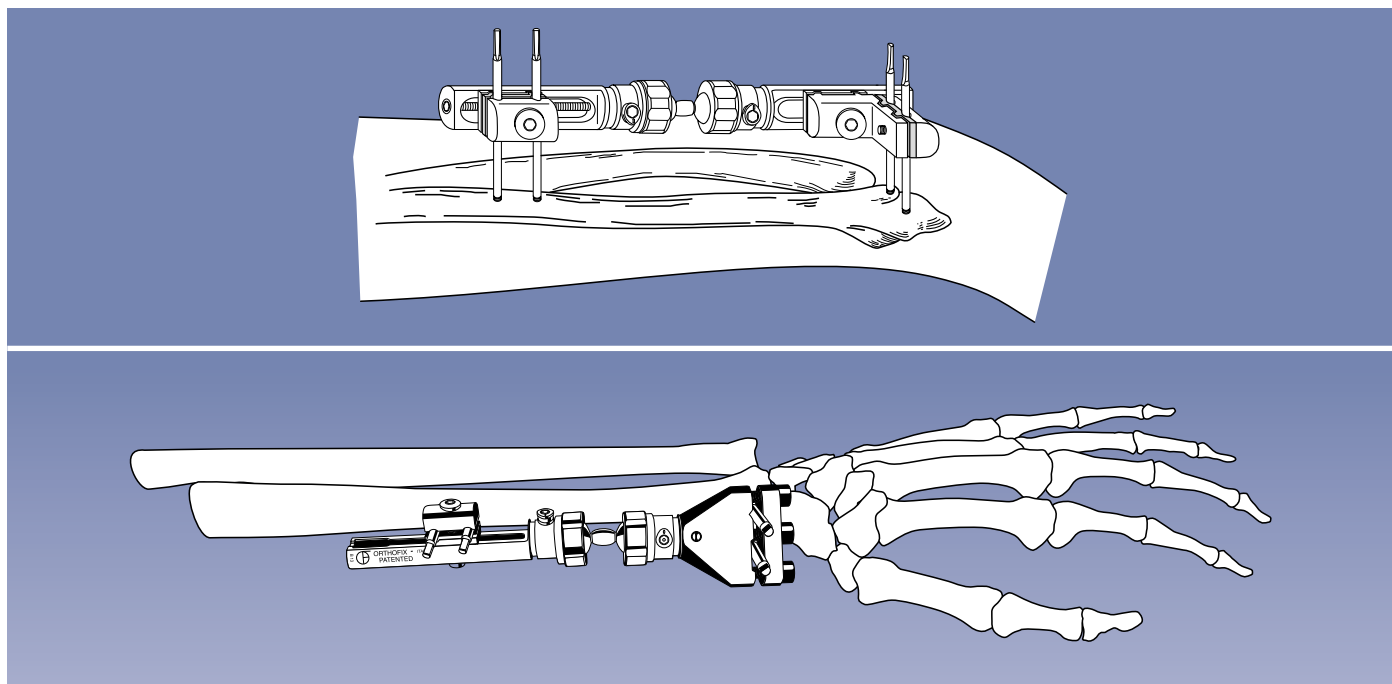


WARNING: All equipment should be carefully examined prior to use to assure proper working condition. If a component or instrument is believed to be faulty, damaged or suspect, it should NOT BE USED.



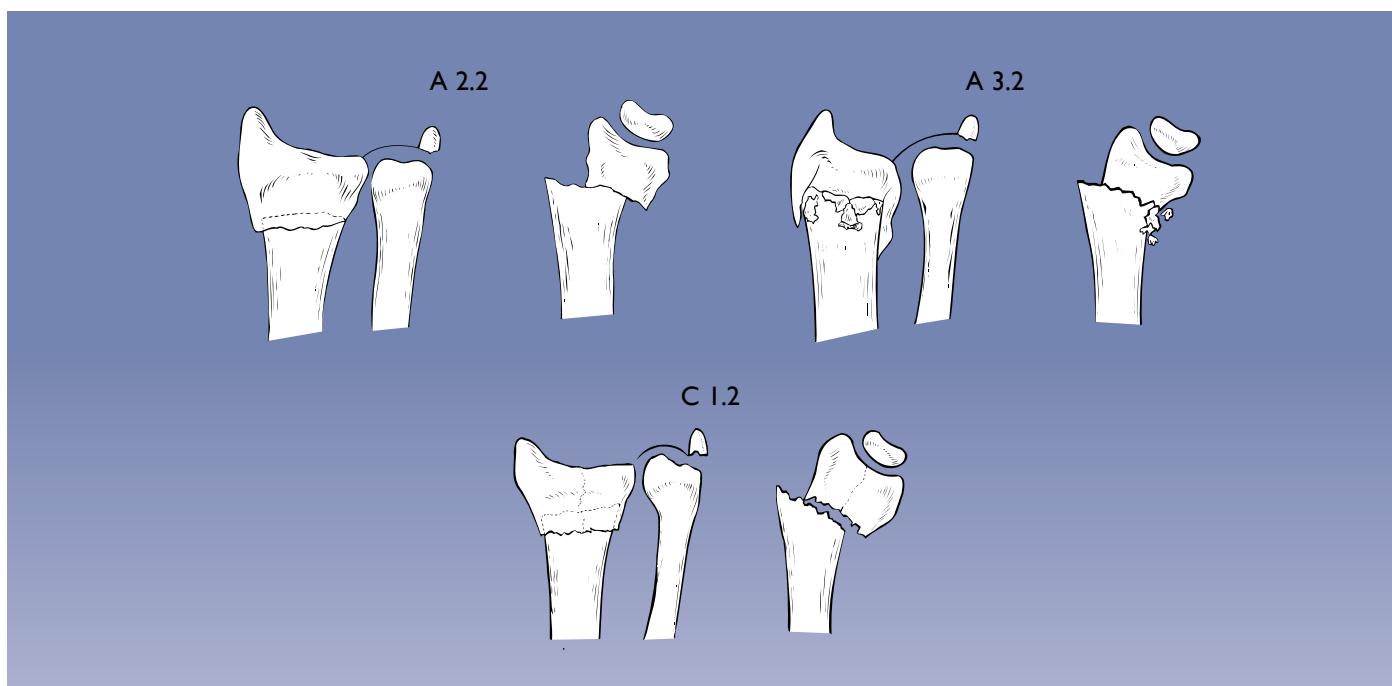
If the extra-articular configuration is not available ready-assembled (37002), this may be constructed as follows:

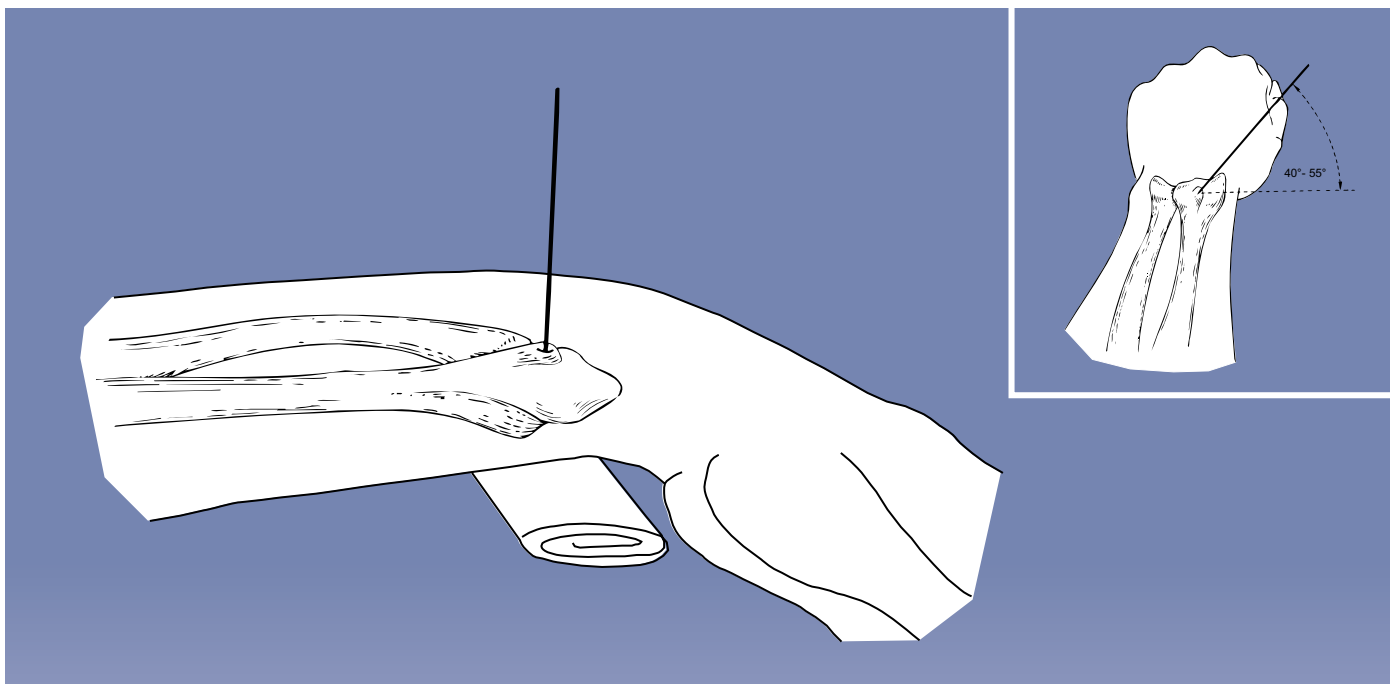
- The T-clamp (37090) is mounted on the short module (37010) by removing the screw retaining the clamp cover of the straight clamp, which is not used, and using this screw to anchor the T-clamp in place as shown.
- The cams and bushes are assembled as described above.
- The compression-distraction module (37060) completes the assembly.



OPERATIVE TECHNIQUE

If there is no intra-articular involvement of the fracture line and the epiphyseal fragment has a volar length of 10mm minimum, bridging of the joint is not required and one of the above extra-articular assemblies is used.



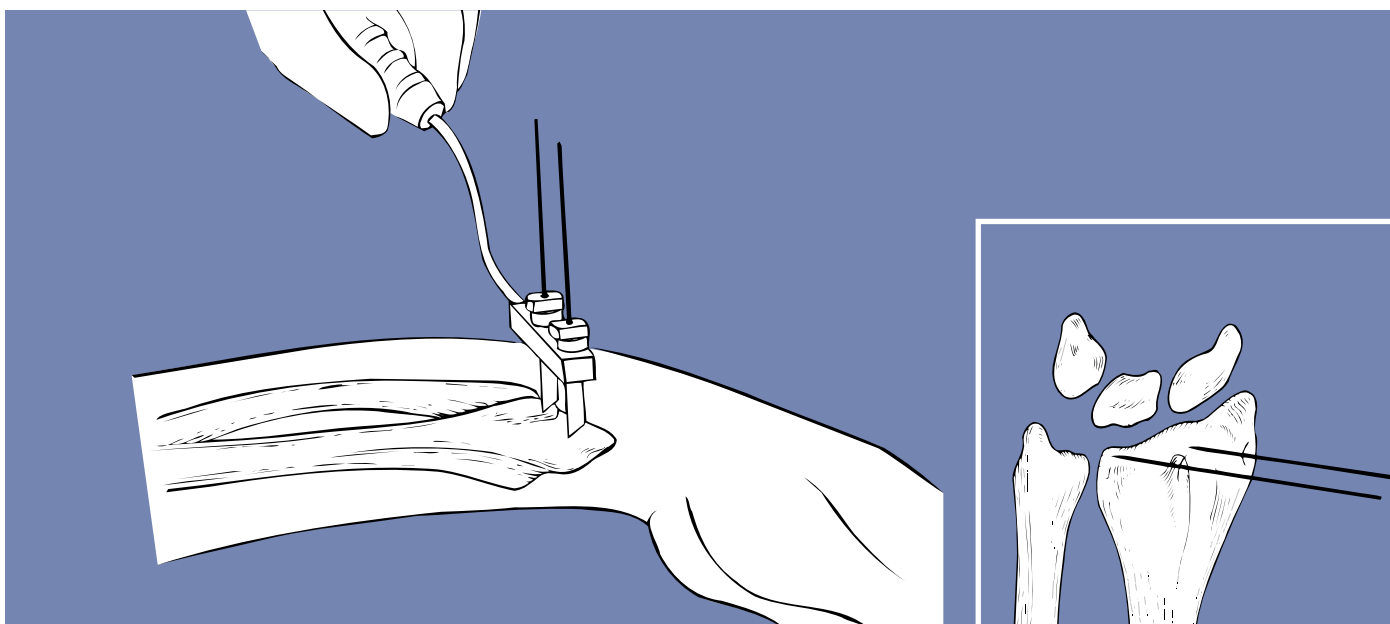


Insertion of the Distal Screws

Pre-operative preparation of the arm includes shaving of the skin surfaces and washing of both the forearm and hand. A hand table is used and a tourniquet is mandatory. Lister's Tubercle is identified and a 10mm incision is made over it. The bone must be exposed prior to insertion of the first 1.5 or 1.6mm Kirschner Wire. The plane of insertion of this wire is about 45° (40°-55°) to the frontal plane. A template with handle, with one screw guide and one pilot wire guide is slid over this Kirschner Wire after its position has been checked radiographically.



PRECAUTION: During and after insertion of the implants, ensure their correct positioning under Image Intensification.



The second screw guide is now introduced and the second pilot wire guide placed inside it. A second 1.5 or 1.6mm Kirschner Wire is now inserted parallel to the first, following a 10mm stab incision and exposure of the bone in the area of the radial styloid. During insertion it is helpful to aim for the solid cortex of the volar lip, but care should be taken to avoid penetration of the wrist joint.



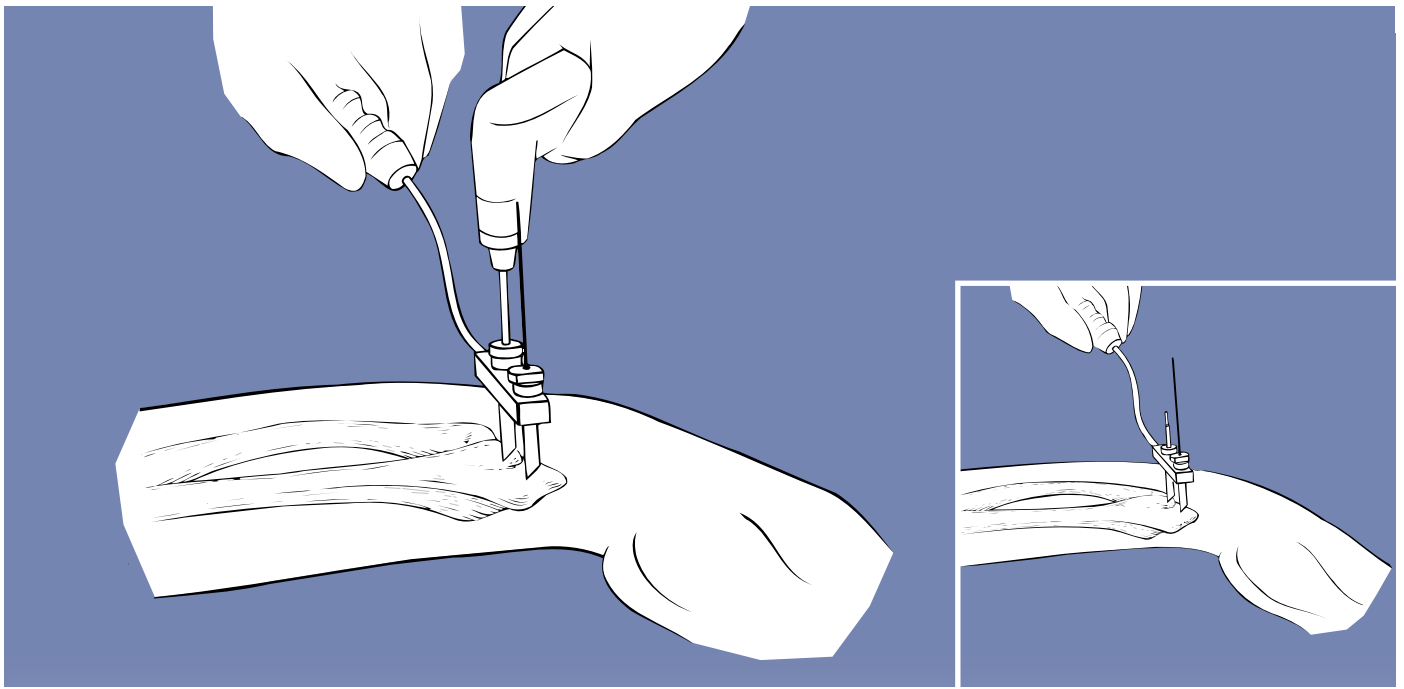
WARNING: During screw and wire insertion, do not enter the joints or the growth plates in pediatric patients to avoid joint damage or growth impairment.

The template with handle is removed and a radiological check of the positions of both Kirschner Wires carried out in two planes.



PRECAUTION: During and after insertion of the implants, ensure their correct positioning under Image Intensification.

If necessary, one or both Kirschner Wires may be re-sited.



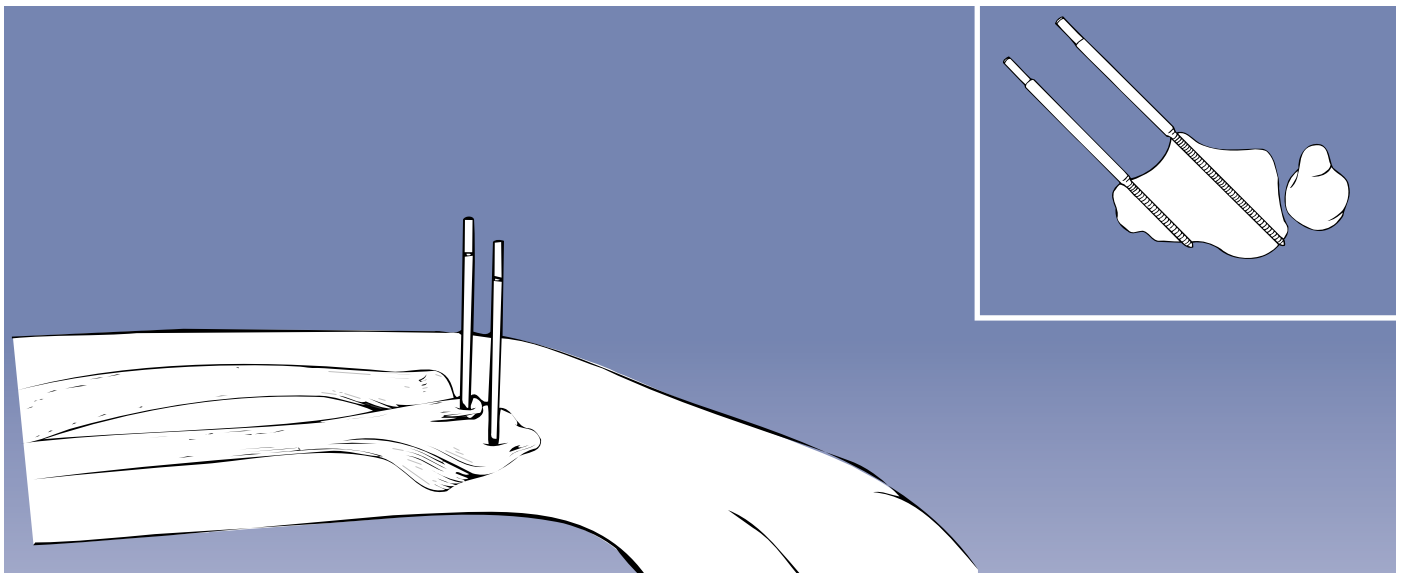
When the positions of the Kirschner Wires are deemed satisfactory, the template with handle, together with screw guides and pilot wire guides, is replaced. The Kirschner Wire in Lister's Tubercle is then removed together with its pilot wire guide and a 2.7mm drill guide inserted. Pre-drilling is carried out with the 2.7mm drill bit and an 80/35mm screw inserted. This screw must be advanced very carefully under Image Intensification in order to avoid over-penetration of the volar cortex.



PRECAUTION: During and after insertion of the implants, ensure their correct positioning under Image Intensification.



PRECAUTION: Any attempt to back out a conical screw once it has been inserted may cause it to become loose.



The second Kirschner Wire is now removed together with its pilot wire guide and drilling for the second screw carried out. Depending upon the size of the radial styloid a 70/20 or an 80/35 screw should be used. A radiographic check at the end of screw insertion is mandatory. The screw should engage the volar cortex securely and penetrate by one thread.

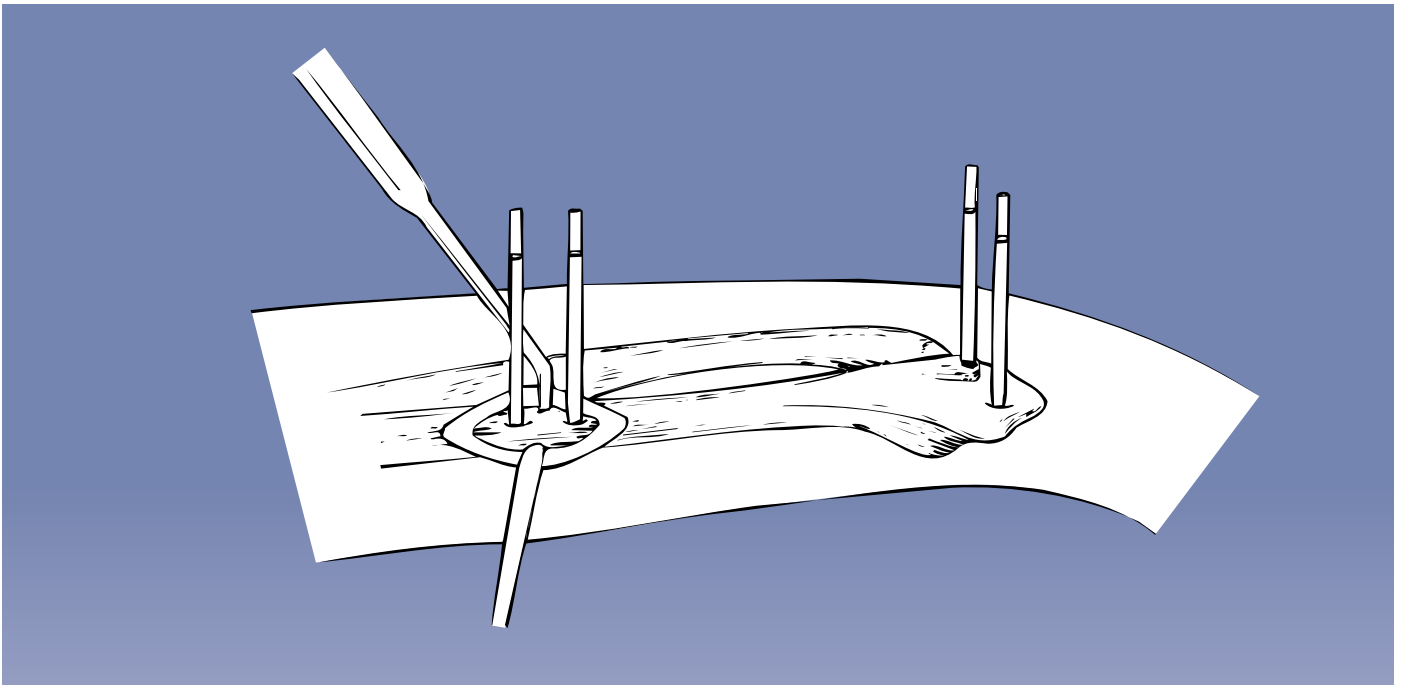


PRECAUTION: During and after insertion of the implants, ensure their correct positioning under Image Intensification.

Penetration of the radio-ulnar joint however, must be avoided.



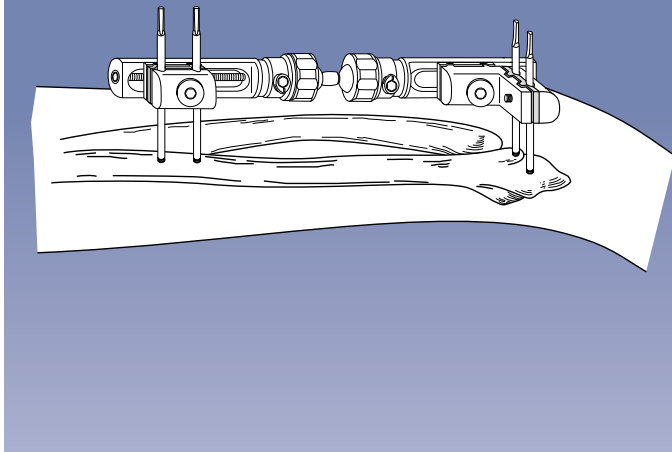
WARNING: During screw and wire insertion, do not enter the joints or the growth plates in pediatric patients to avoid joint damage or growth impairment.



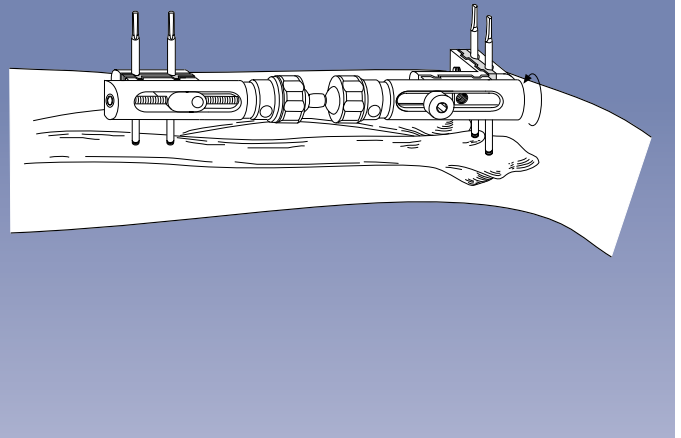
Insertion of the Proximal Screws

Insertion of the proximal screws is carried out at a distance of about 14cm from the distal screws. The fixator may be mounted temporarily on the distal screws. The skin is then marked to indicate the position of the proximal screws and the fixator removed for screw insertion. Alternatively, the cover of the clamp of the proximal module may be replaced with the template/conversion clamp (13710) (see page 32), the fixator mounted to the distal screws and the screw guides inserted into the template/conversion clamp. The proximal screws are inserted through a 25mm incision in order to avoid injury to the superficial branch of the radial nerve. Again, a plane of insertion 45° to the frontal plane is chosen and the appropriate screws inserted after drilling with the 2.7mm drill bit. In most instances 70/20mm screws will be employed.

Check free extension of hand



Check free extension of hand



Using the T-Clamp (37090)

The fixator is mounted with the compression-distraction module placed proximally and the short module with T-clamp distally. **Ensure that both ball-joint security collars of the fixator are fully tightened.** Where the proximal screws have been applied with the fixator already mounted, the template/conversion clamp should be replaced with the definitive clamp cover. Reduction of the fracture is not necessary prior to mounting of the fixator. The templates with handles are now placed over each pair of screws to assist in fracture reduction. Once reduction has been achieved, all clamp cover and clamp anchoring screws are tightened using the T-wrench or Allen Wrench, ensuring that bone screws are housed in the clamp and base plate seats. **Take care that the fixator module is held firmly while tightening to avoid loss of position.** To tighten the double ball-joint, the cam is turned **clockwise** until very tight, so that the dot rotates a minimum of 90 and a maximum of 170 degrees.

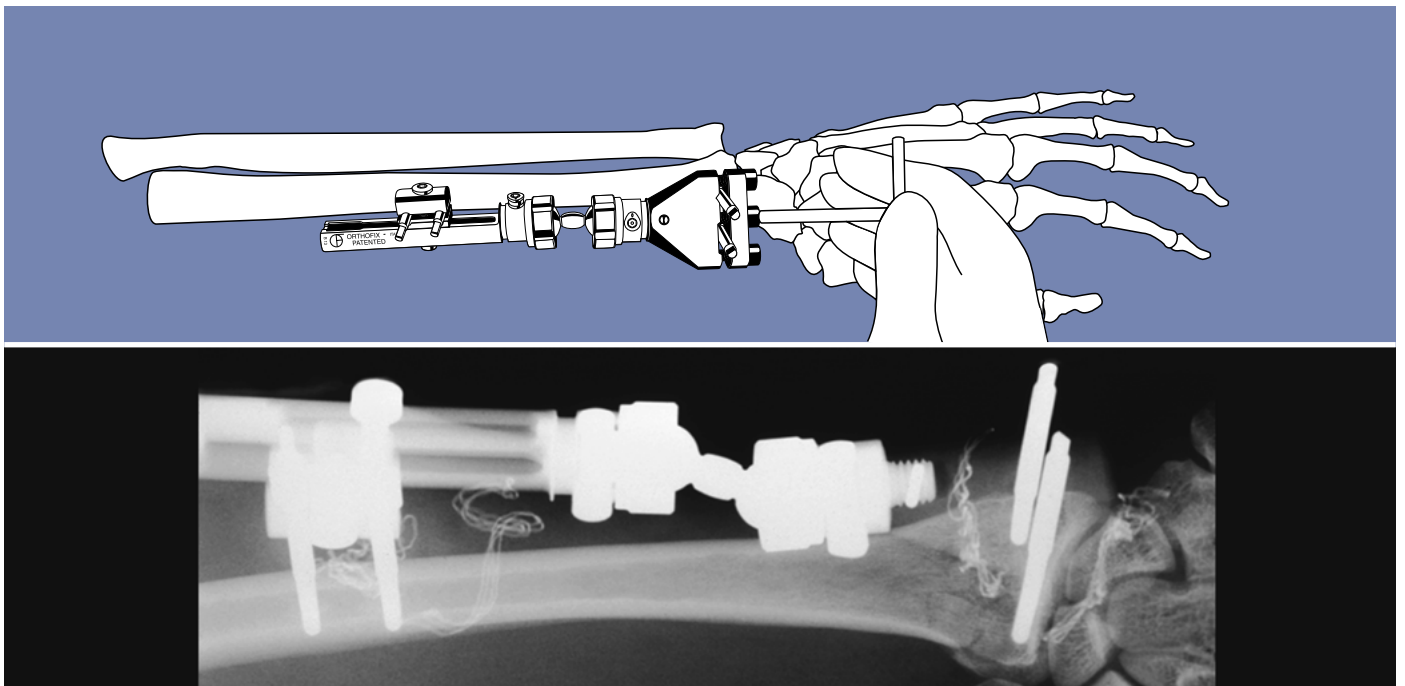


WARNING: If the ball-joint is rotated in excess of 170° degrees, it may become loose.

The fixator should be placed in such a way that it does not obstruct the lateral or AP X-ray and the alternative positions possible are shown above. Post-operative dressings are applied around the screws, but a circular dressing is not recommended. Tightening of the fixator screws should be checked at least once again, and tightness of the ball-joint security collars of the fixator should be checked at regular intervals.



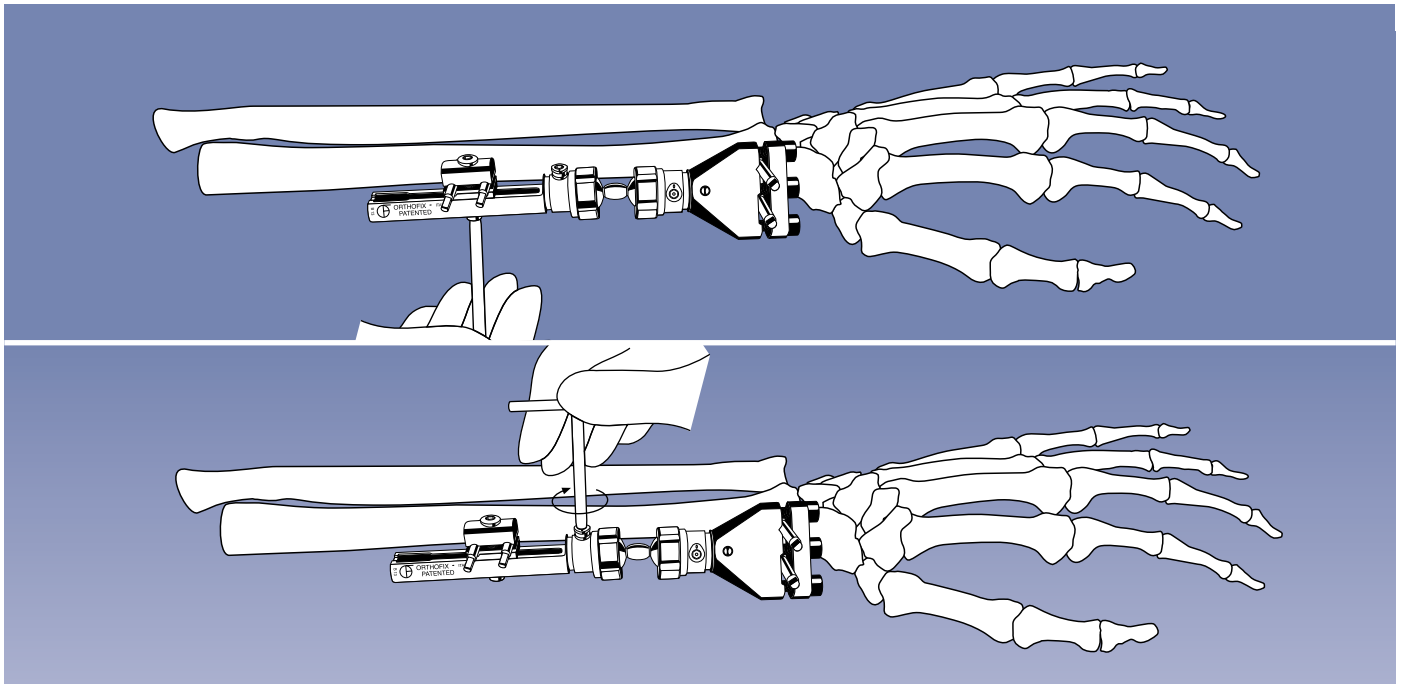
PRECAUTION: The surgeon must evaluate the integrity of the construct at follow-up visits.



Using the Extra-articular Radiolucent Wrist Clamp (37070)

Mount the fixator with the sliding module proximally and the Extra-articular Radiolucent Wrist Clamp distally with the screw in the Lister's Tubercle housed in the fixed screw seat. Ensure that both ball-joint security collars are fully tightened. Tighten all clamp cover screws.

To tighten the clamp cover of the Radiolucent Clamp, tighten the central locking screw first to avoid tilting the cover. Then tighten each screw until the Allen Wrench slips in the hexagon in the screw head. The locking screws of this clamp should be replaced after every use. To loosen these screws, insert the end of a 3mm Allen Key into one of the holes in the edge of the screw head, and turn the screw anti-clockwise. Reduce the fracture. The Extra-articular Radiolucent Wrist Clamp allows for visualisation of the fracture site.



Tighten the clamp anchoring screw and complete locking of the double ball-joints by turning the cams clockwise until very tight (dot moves between 90° and 170°). The Extra-articular Radiolucent Wrist Clamp allows for convergent placement of the second distal screw. Convergent placement may be used if the radial epiphysis is very small, but the surgeon should be aware that this type of screw placement may lead to impingement of the soft tissues and reduced bone purchase. This procedure is therefore recommended only for surgeons with substantial experience in wrist surgery. When convergent screw placement is to be used, insert the screw in Lister's Tubercle in the usual manner at 45° to the frontal plane. Apply the clamp over this screw and introduce a pilot wire guide into the second screw seat down to the bone through a 10-15mm incision. Insert a K-wire and confirm its position in two planes; remove the clamp and place the template with a pilot wire guide and single screw guide over the wire. Holding the handle of the template steady, remove the wire, drill the wire track as above through a drill guide, and insert a 70/20mm screw. After insertion of this screw, remove the template and apply the clamp. The proximal screws are then inserted as above.

EQUIPMENT REQUIRED

| |
|--|
| Pennig Dynamic Wrist Fixator (37000) - complete |
| • 2 Screw Guides/Templates with handles (13520) |
| • 1 Drill Guide 2.7mm diameter (13530) |
| • 1 Tapered Trocar (13540) |
| • 1 Drill Bit Kit 2.7mm diameter (13550) |
| • 1 T-Wrench for Clamp Screws (13570) |
| • 1 T-Wrench for Bone Screws (M210) |
| • 4 Cortical Screws 70/20 or 80/35 3.0-3.3mm thread diameter (35100 or 35101) |
| • Ulnar Outrigger Clamp (37050) |
| Special kit for small metacarpals (13555) consisting of: |
| • 4 Cortical Screws 70/20 2.5-3.0mm thread diameter (35156) |
| • 1 Drill Guide 2.0mm diameter (13531) |
| • 1 Drill Bit 2.0mm diameter (13551A) |
| • 1 Drill Stop 2.0mm diameter (13552) |
| • 1 3mm Allen Wrench (10012) |
| <i>The 2.0mm drill bit and drill guide, and the 2.5-3.0mm screws for which they must be used, are identified by a roughened surface.</i> |

ADDITIONAL INSTRUMENTATION (not provided)

| |
|---------------------------------|
| • 2 Langenbeck Retractors-Small |
| • Adson Forceps |
| • Scalpel (N° 11) |
| • Small Scissors |
| • Air Drill |

THE ORTHOFIX FRAGMENT FIXATION SYSTEM

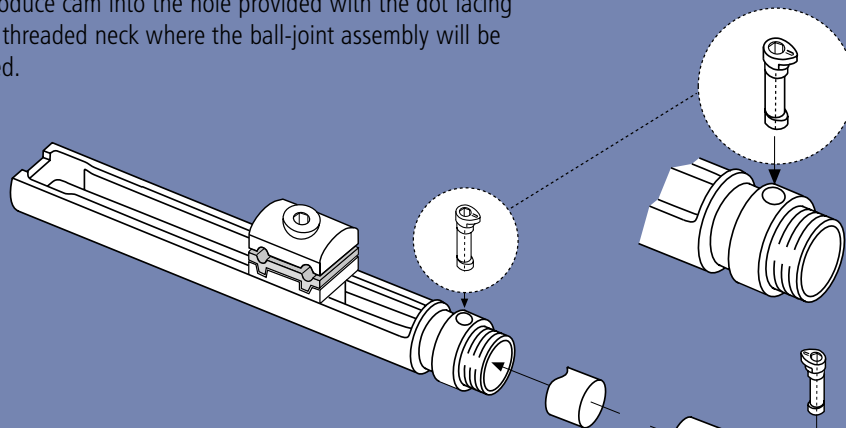
This system comprises fixation wires with a 2.0mm shank diameter and a 1.6mm thread diameter. The total length is 120mm and different thread lengths are available as follows:

| Thread Length (mm) | Code N° |
|--------------------|---------|
| 11 | W1611 |
| 13 | W1613 |
| 15 | W1615 |
| 17 | W 1617 |
| 19 | W1619 |
| 21 | W1621 |
| 23 | W1623 |
| 25 | W1625 |
| 30 | W1630 |
| 35 | W1635 |
| 40 | W1640 |
| 45 | W1645 |

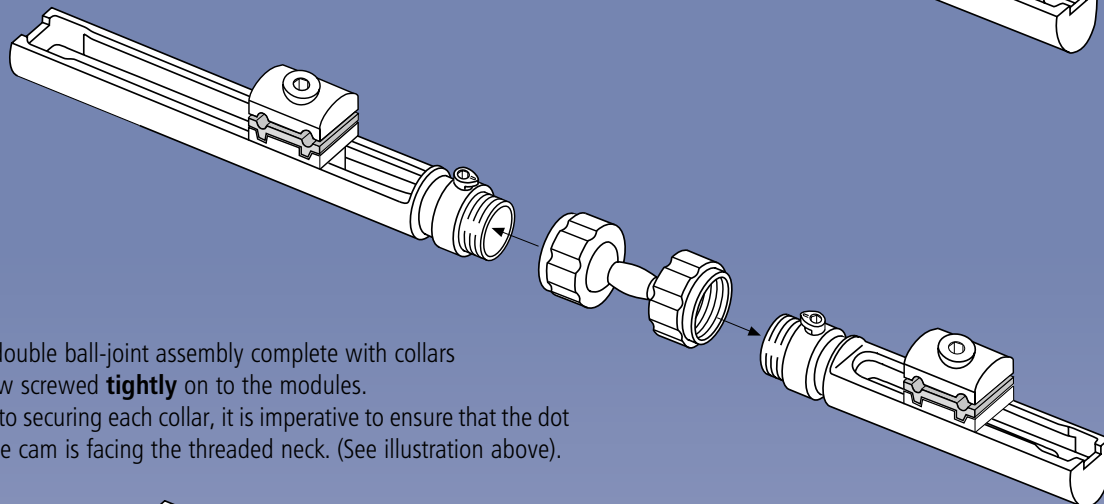
Washers with a diameter of 4mm (W1600) are available for use in situations where there is osteoporosis or any comminution of the cortex.

RE-ASSEMBLY FOLLOWING STERILIZATION

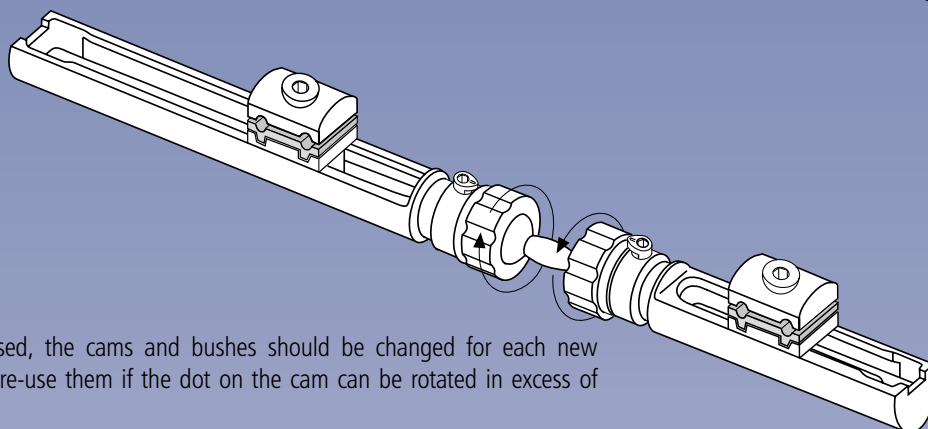
1. Introduce cam into the hole provided with the dot facing the threaded neck where the ball-joint assembly will be fitted.



2. Align the groove on the bush with the long axis of the cam and seat components within the recess.



3. The double ball-joint assembly complete with collars is now screwed **tightly** on to the modules. Prior to securing each collar, it is imperative to ensure that the dot on the cam is facing the threaded neck. (See illustration above).



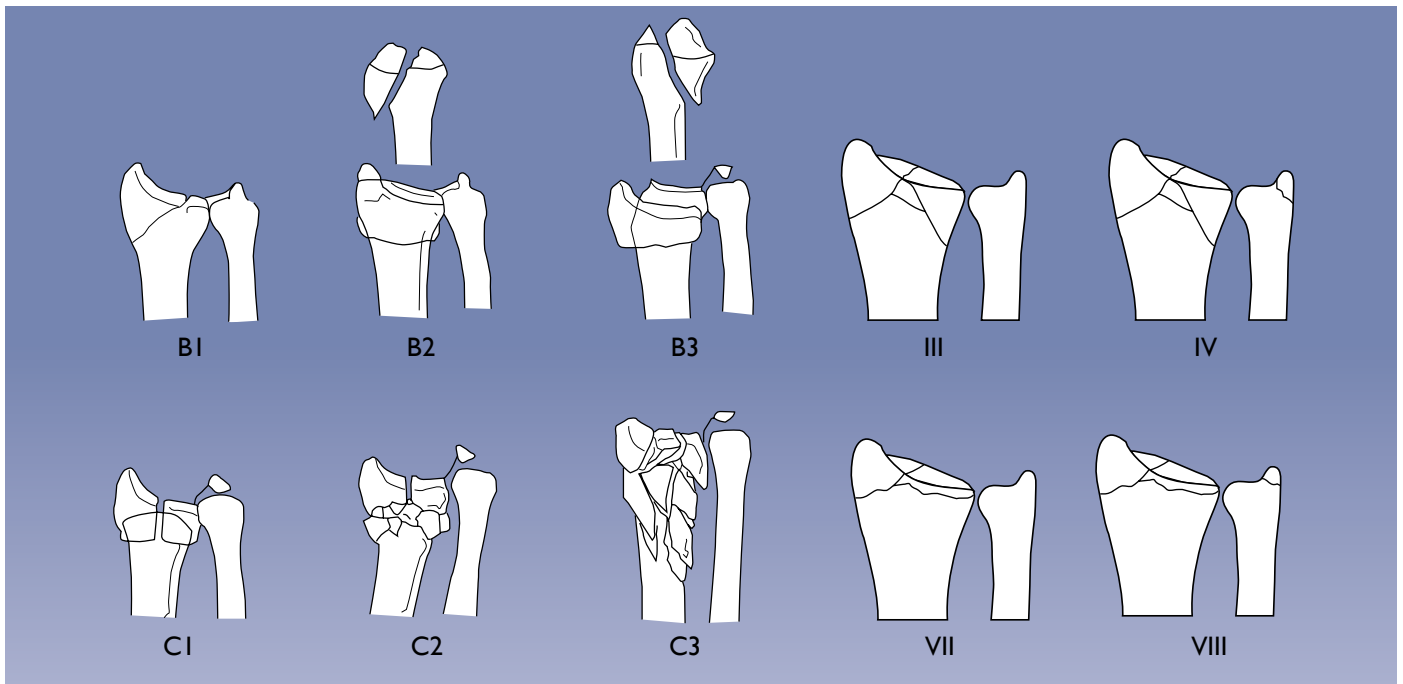
If the fixator is reused, the cams and bushes should be changed for each new application. Do not re-use them if the dot on the cam can be rotated in excess of 170 degrees.



WARNING: If the ball-joint is rotated in excess of 170° degrees, it may become loose.

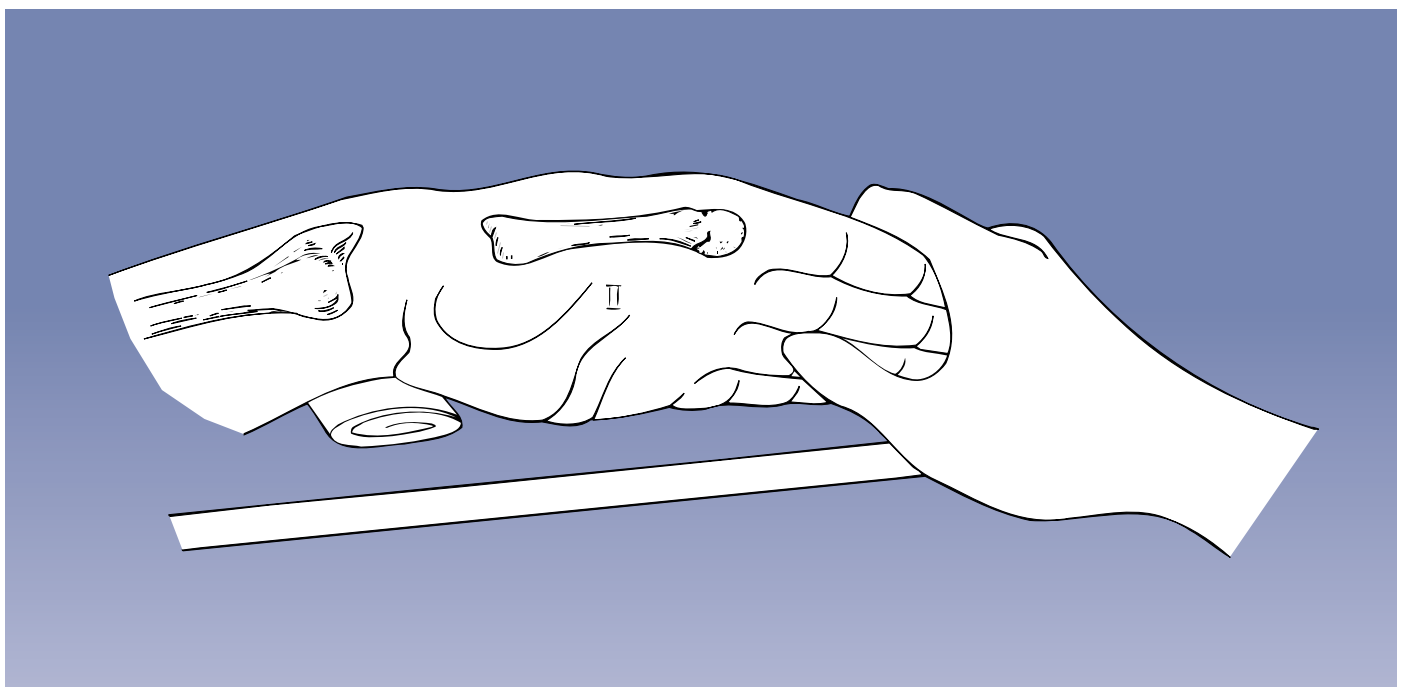


WARNING: All equipment should be carefully examined prior to use to assure proper working condition. If a component or instrument is believed to be faulty, damaged or suspect, it should NOT BE USED.



OPERATIVE TECHNIQUE

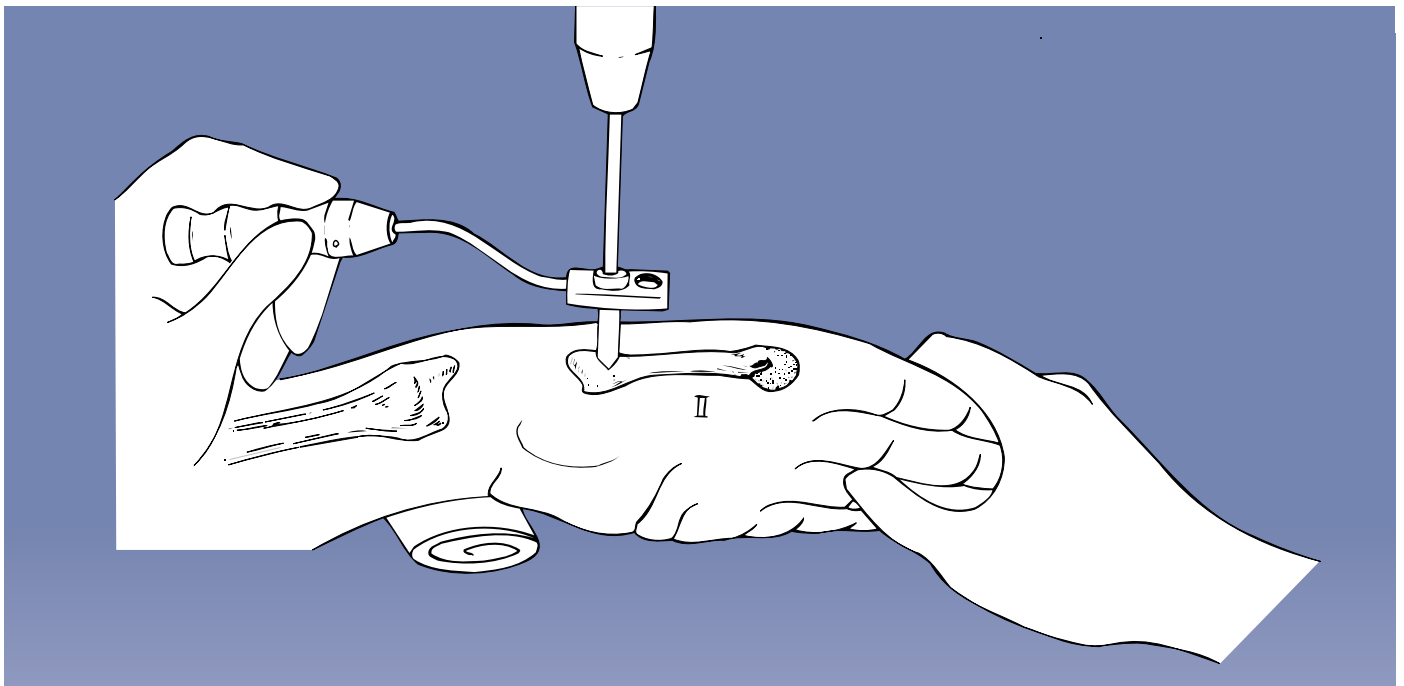
With very short peri-articular fragments where two screws cannot be inserted or in displaced intra-articular fractures, bridging of the joint is necessary. For the successful application of this technique, the individual characteristics of each case must be taken into account. A tourniquet may be used. Pre-operative preparation of the arm includes shaving of the skin surfaces and washing both the forearm and hand.



A hand table is used. Pre-operative fracture reduction can, but does not have to be, carried out.

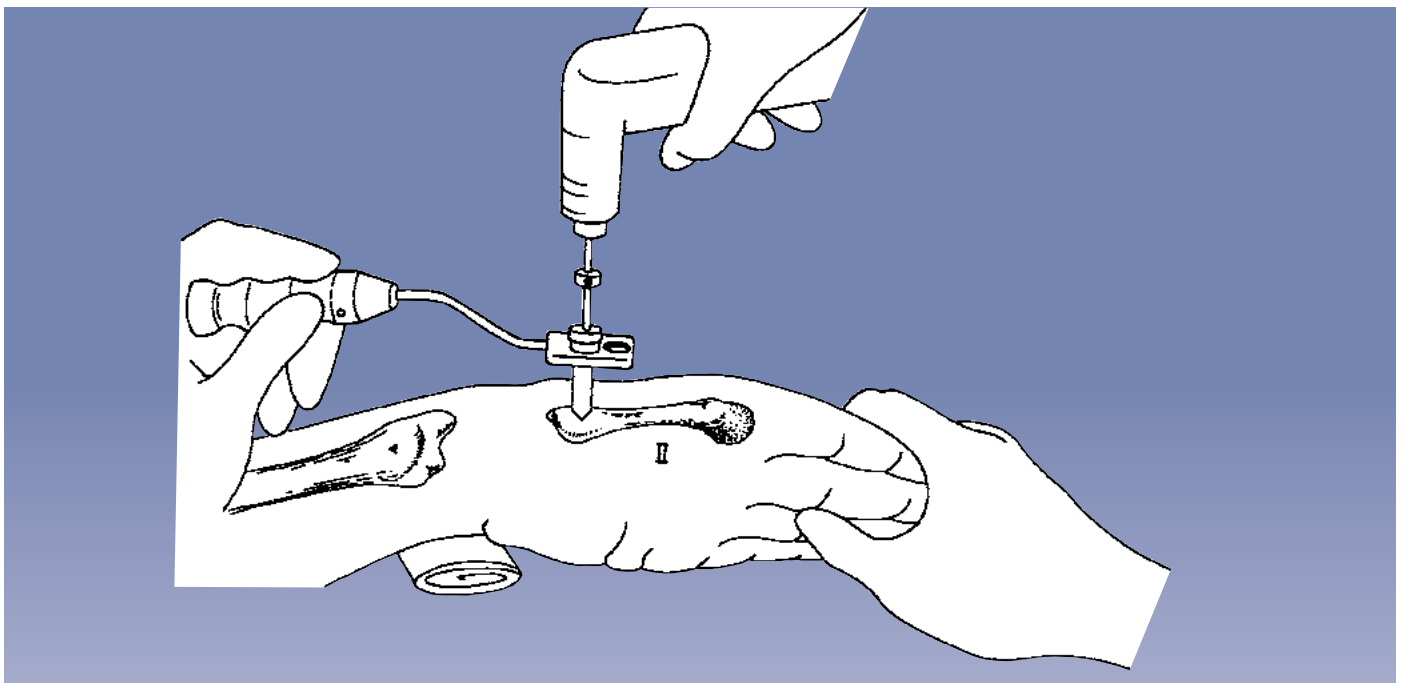
The wrist will usually be placed in moderate (manual) traction, flexion and radial abduction (i.e. ulnar deviation) with a folded towel on the ulnar side to support it.

The fixator is applied to the second metacarpal and the middle/distal third of the radius. The second metacarpal and the distal radius are shown.



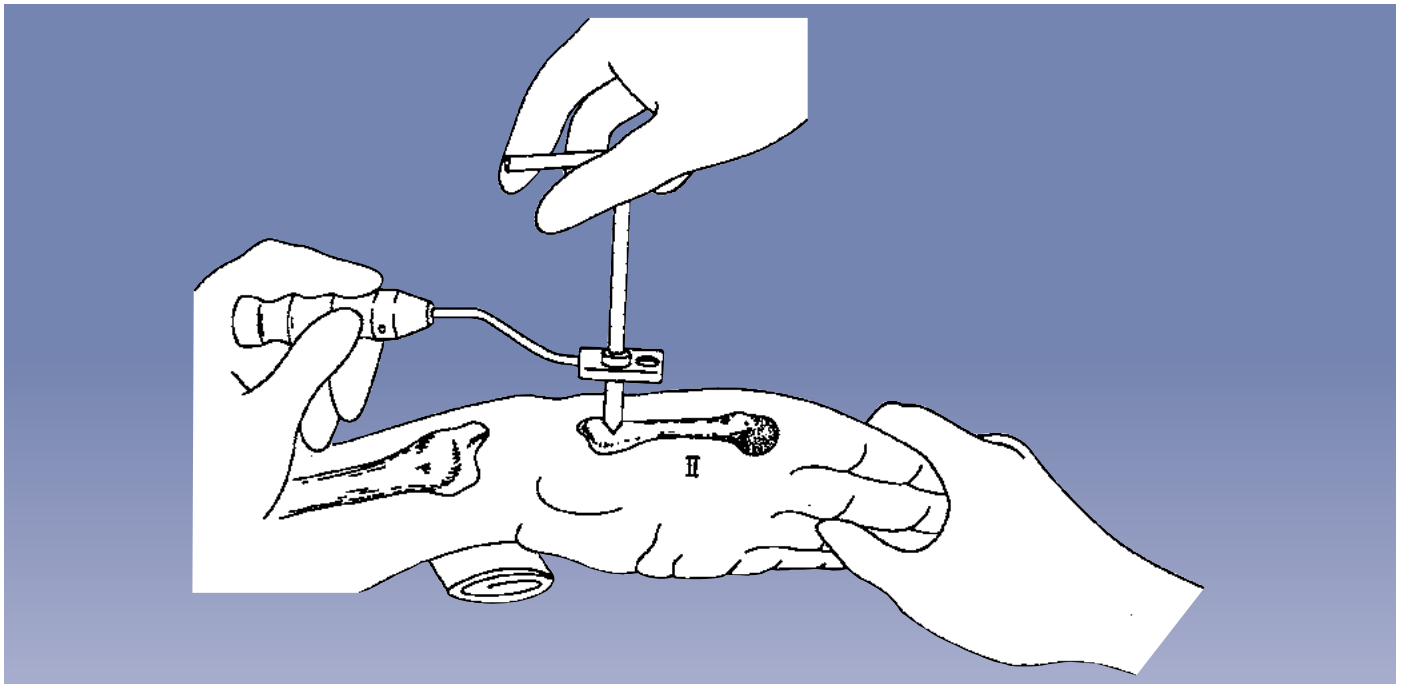
Insertion of the Distal Screws

The position of the screws determines the position of the fixator. Screws should be introduced in the **frontal plane** on the radial side so that wrist mobilization may be implemented at a later stage if desired, without displacement of the fracture fragments and to enable slightly oblique, unobstructed lateral X-rays to be taken. The proximal metacarpal screw is inserted first, positioned close to the base of the bone on the flare of the tubercle. A stab incision is made and the soft tissue is dissected down to the bone, the center of which is then located using the trocar within the short screw guide placed through the template with handle.



The trocar is removed and a drill guide inserted into the screw guide. A 2.7mm drill bit is used and both cortices are drilled.

When the far cortex is reached, the drill stop is locked on to the drill bit 5mm above the drill guide. The far cortex is then drilled. This will prevent the drill bit from damaging the interosseus muscles.



Cortical 3-3.3mm thread and 4mm shank diameter, 70/20mm length screws are suitable for most applications both in the metacarpal and the diaphysis of the radius. An 80/35mm screw is also available.

Screws with a smaller thread (2.5-3.0mm) are available. These should only be used in the metacarpal diaphysis when the outer diameter of the bone is less than 9mm. A 2.0mm drill bit is used for the insertion of these screws. The proximal screw is now inserted into the second metacarpal through the screw guide to a depth of about 10mm (i.e. half the thread length) using the T-wrench.

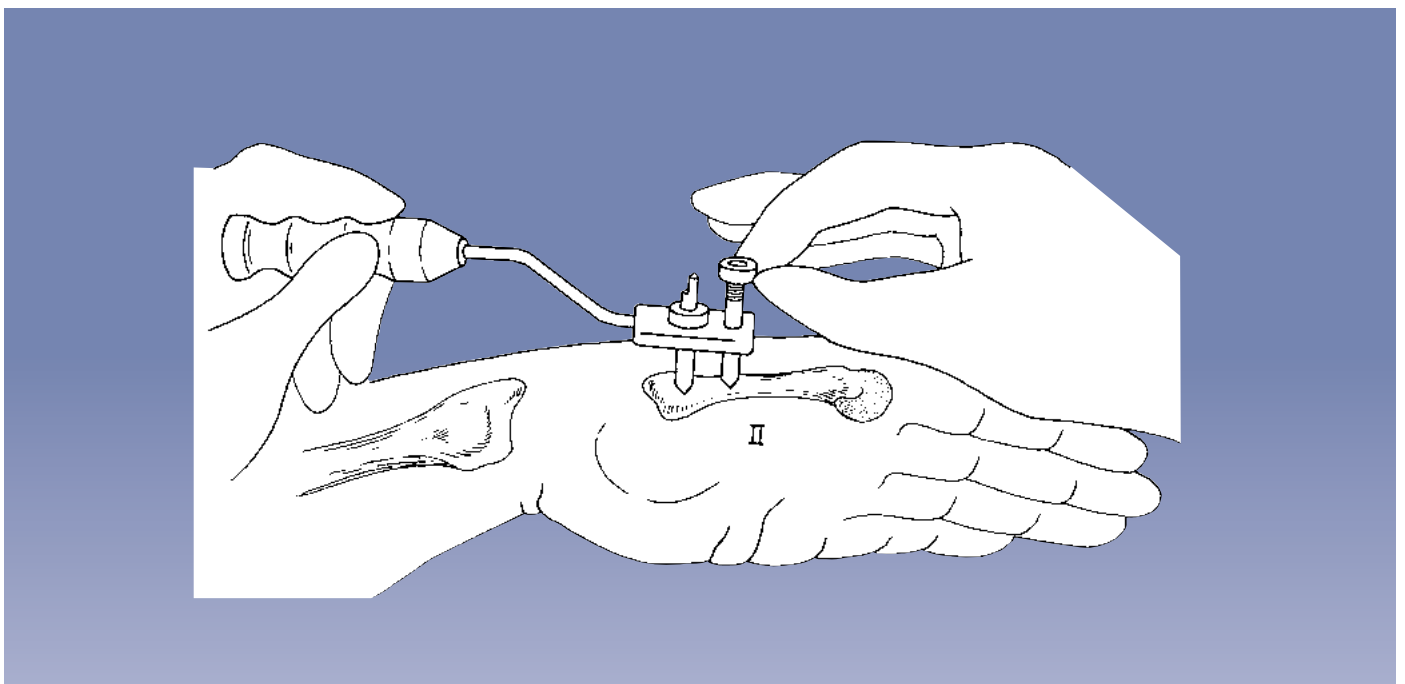
An Image Intensifier should be used to verify the position and penetration of the far cortex by all 4 screws when they have been sited.



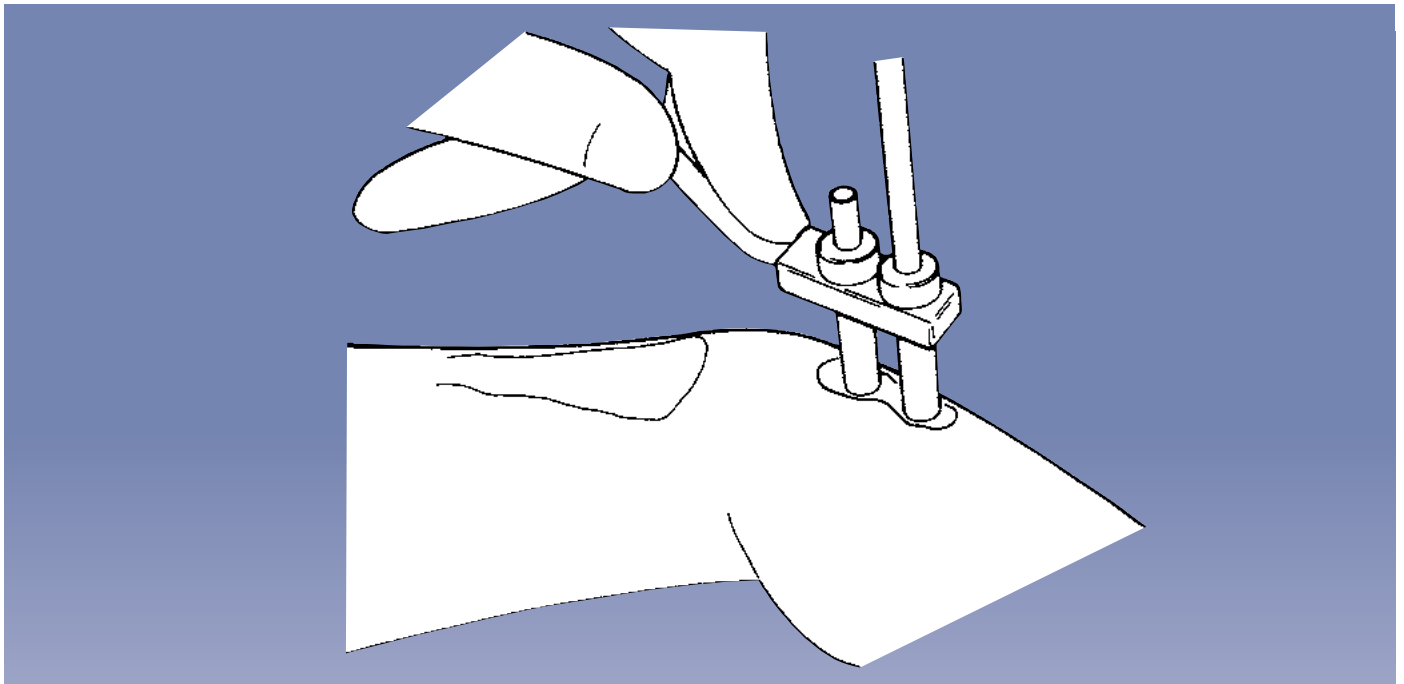
PRECAUTION: During and after insertion of the implants, ensure their correct positioning under Image Intensification.



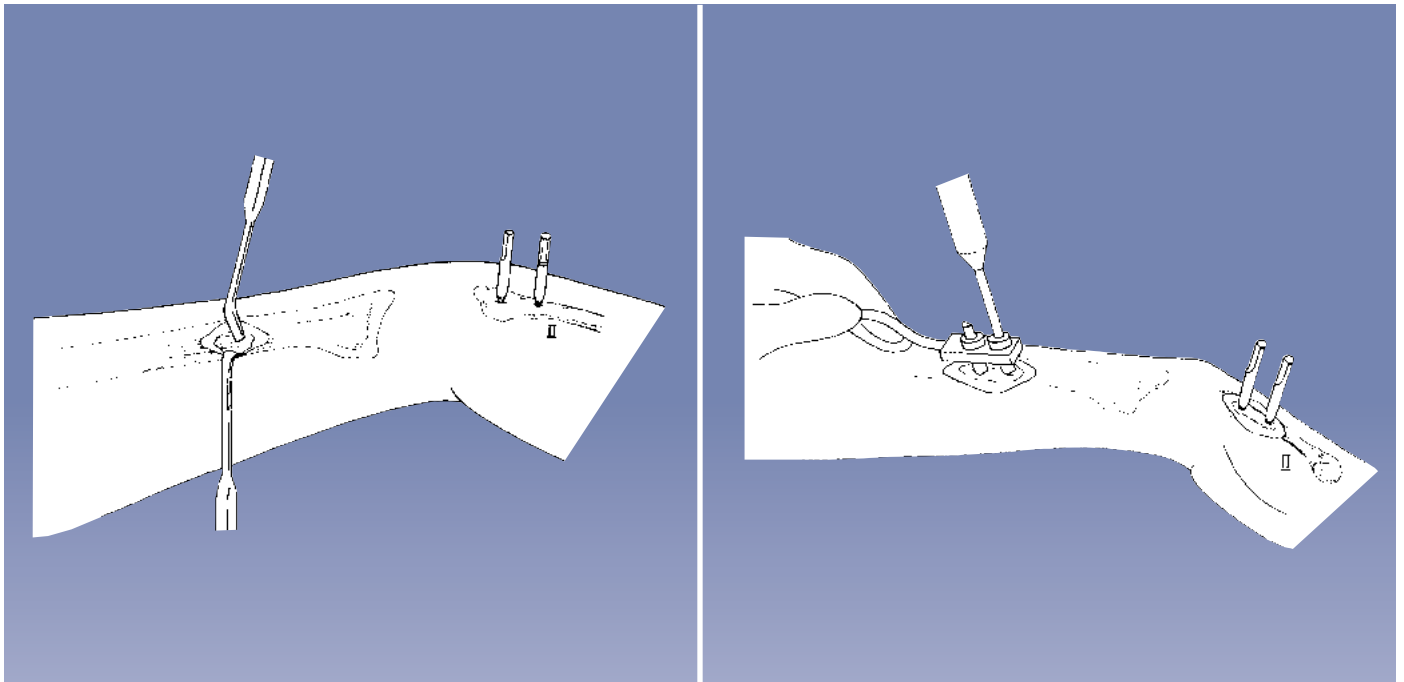
PRECAUTION: Any attempt to back out a conical screw once it has been inserted may cause it to become loose.



This shows the proximal metacarpal screw in place. The longer screw guide is now fully inserted into the template and the procedure is repeated, starting with a stab incision as before.



The second metacarpal screw is shown being inserted.



Insertion of the Proximal Screws

Prior to insertion of the screws into the radius, the bone is exposed following a 25mm long incision with the distal radial screw being placed no closer than 40mm to the fracture site.

Care should be taken not to sever the superficial branch of the radial nerve or any extensor tendons. Blunt retractors should be used.



PRECAUTION: Screws must be inserted with full knowledge of the safe corridors to avoid damage to the anatomical structures.

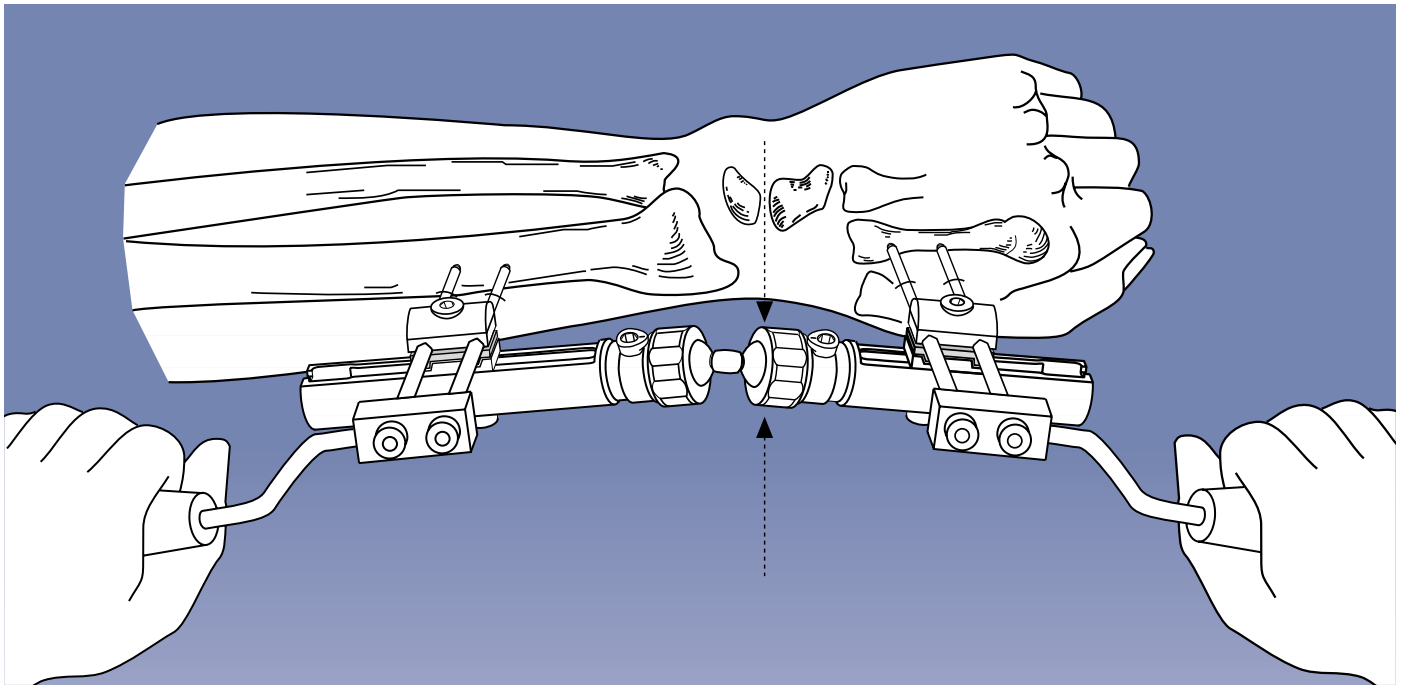
The steps described for insertion of the metacarpal screws should now be repeated for the two radial screws. At this point full penetration of the far cortex by all four screws is checked with the Image Intensifier.



PRECAUTION: During and after insertion of the implants, ensure their correct positioning under Image Intensification.



PRECAUTION: Any attempt to back out a conical screw once it has been inserted may cause it to become loose.



Fixator Application

The fixator should be fully assembled exactly as shown on page 13. It is essential that the dot on the cam is facing the threaded neck before each security collar is tightened. **Failure to follow this procedure exactly may result in loosening of the collars.** The collars are now fully screwed home. With all other screws loosened, the fixator is applied to the bone screws already in situ, positioning it at a distance of 15-20mm from the skin. Reduction of the fracture is now carried out under Image Intensification. The two templates with handles with their screw guides in place (see figure above) may be used to manipulate the fragments while distancing the surgeon's hands from the radiation beam.

The design of the fixator with its double ball-joint is such that the fracture fragments can be manipulated in any plane during reduction. This feature is complemented by the fact that the clamps for the bone screws can both slide and swivel on the fixator module as required.

At this point, it is imperative to ensure that the distal ball of the double ball-joint is aligned with the center of rotation of the wrist (the lunate-capitate joint line). Correct positioning can be checked using a K-wire and Image Intensification. The center of the anatomical snuffbox is used as a landmark.



PRECAUTION: During and after insertion of the implants, ensure their correct positioning under Image Intensification.

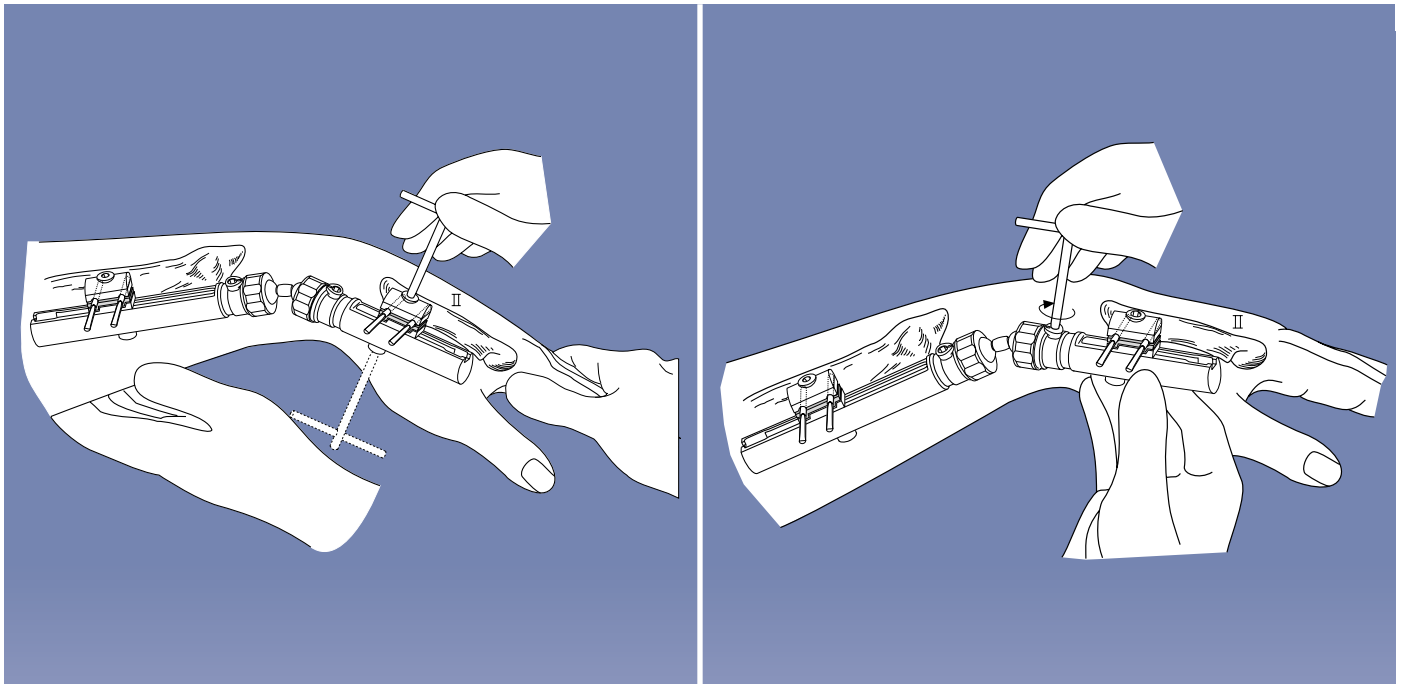
REDUCTION TECHNIQUES

It is important to achieve reduction using gentle manipulation. Excessive flexion, extension or radial abduction should be avoided. It is preferable to push the fragments into place using digital pressure. Traction is only applied manually.

If the radial length has not been restored, grafting (using cancellous bone from the iliac crest) should be carried out.

Grafting should similarly be carried out if there is persistent radial angulation. In intra-articular fractures, displaced articular fragments may be elevated by limited open reduction and subsequently stabilized using the Orthofix Fragment Fixation System.

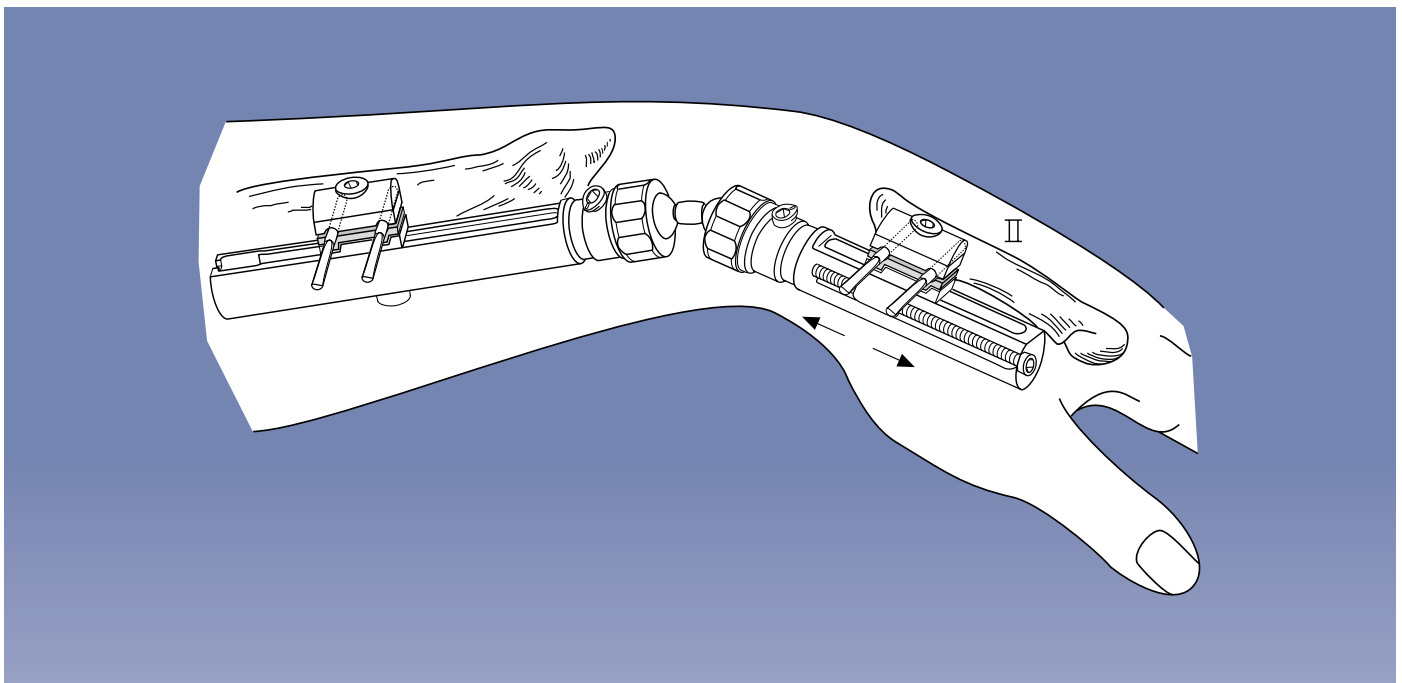
Associated fractures of the ulna or carpal bones should be treated as separate injuries.



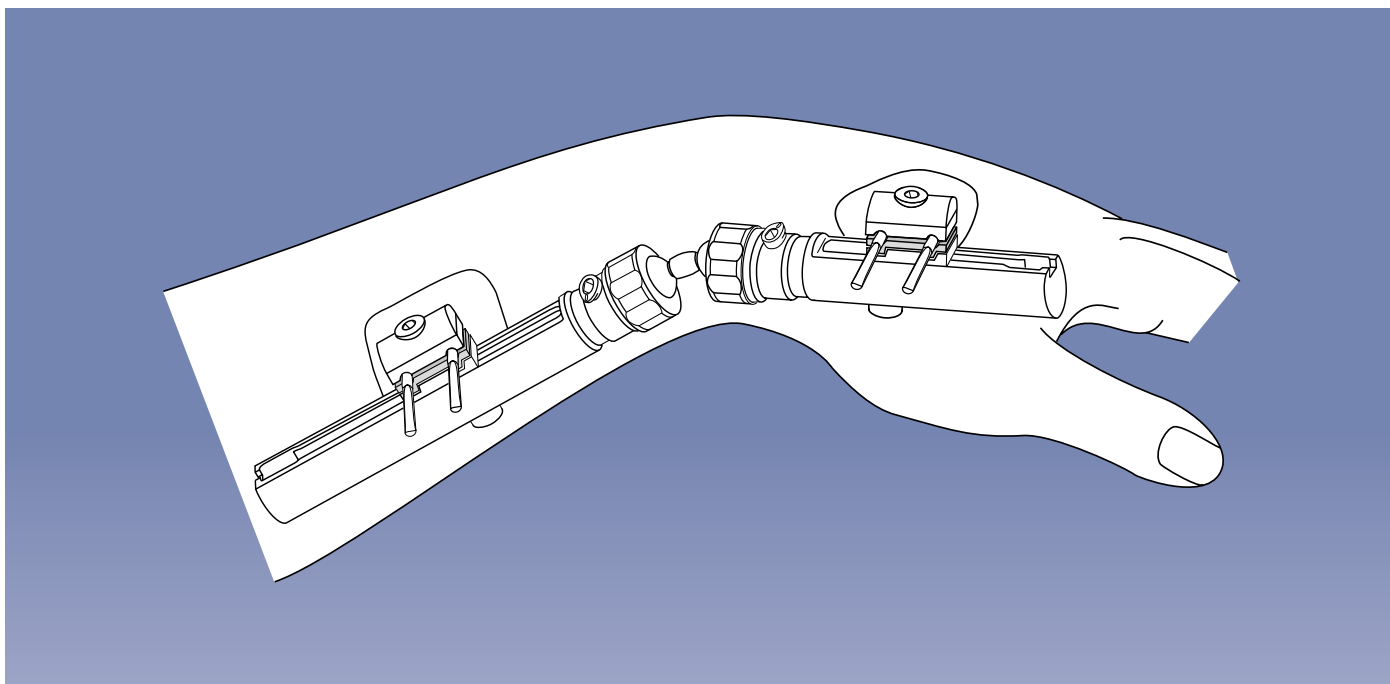
Once reduction has been achieved, all clamp cover and clamp anchoring screws are tightened using the T-wrench or Allen Wrench, ensuring that bone screws are housed in the clamp and base plate seats. **Take care that the fixator module is held firmly while tightening to avoid loss of position.** This illustration shows tightening of the double ball-joint. The cam is turned **clockwise** until very tight so that the dot rotates a minimum of 90 and a maximum of 170 degrees.



WARNING: If the ball-joint is rotated in excess of 170 degrees, it may become loose.

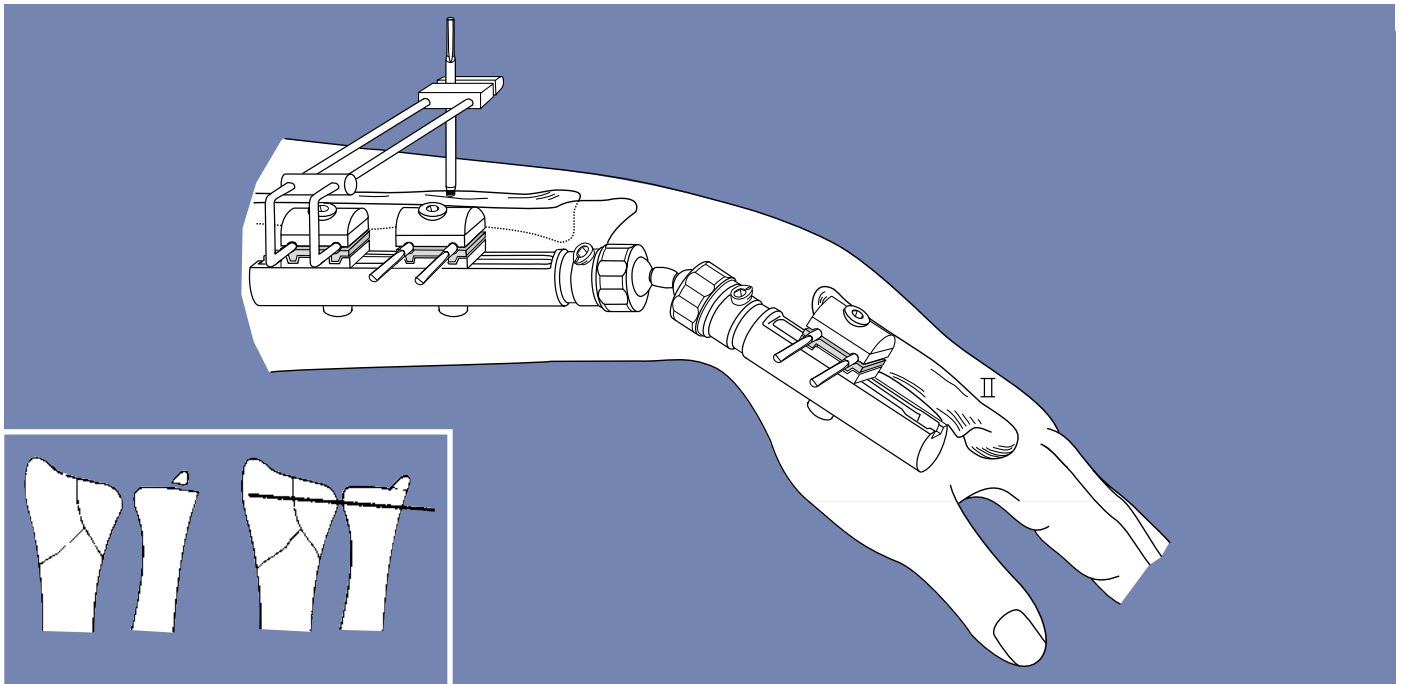


In cases where treatment has been delayed, the compression-distraction module may be used and the wrist joint **temporarily** distracted in a gentle manner to allow joint reconstruction and/or bone grafting. The over-distraction **must be** released at the end of surgery.



At the conclusion of the operation, all blood is removed from the skin. A suture may be used for the radial incision. The incisions are now observed while moving the fingers to detect any skin or soft tissue tethering around the screws that, if present, may require additional skin/soft tissue release. Dry, sterile dressings are applied as shown. It is important to exert gentle pressure with the dressing on the skin to reduce fluid formation beneath the skin edges. A cloth tube may be applied to protect the patient's clothes and the fixator.

Pin Site Care: Please refer to the Orthofix video entitled "Pin Site Care", which is available from your Orthofix representative.



USE OF THE ULNAR OUTRIGGER CLAMP

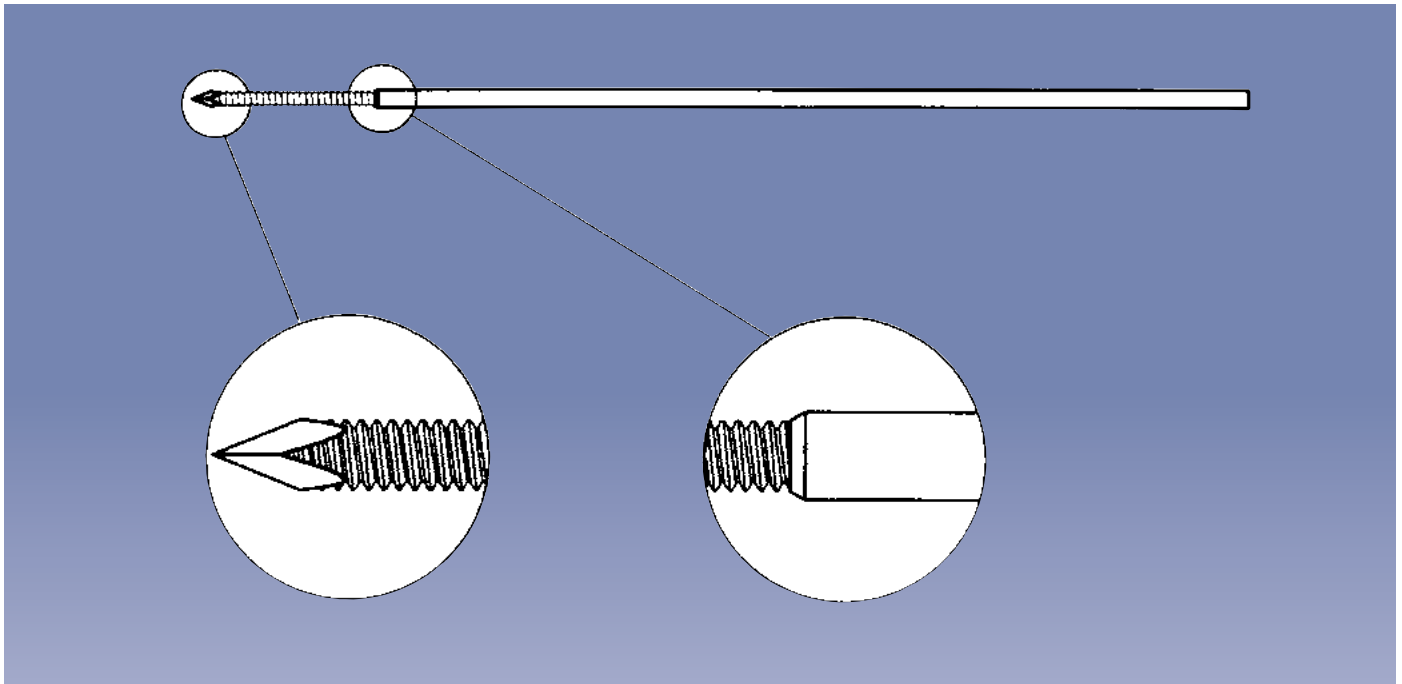
In cases of radio-ulnar instability or an injury to the ulnar disc, the ulnar outrigger clamp (37050) may be used. This device is mounted on a second screw clamp on the radial (long) module. The fixator is used in the manner illustrated to stabilize the radial fracture. The ulna must then be reduced in the neutral position and one or two ulno-radial K-wires (1.5mm) used to secure the distal radio-ulnar joint temporarily. A single 70/20 or 80/35mm screw is then introduced into the ulna following the steps described above. The screw enters the ulna dorsally, so cautious drilling is important to avoid injury to the ulnar artery or nerve. The K-wire(s) are removed at the end of the operation. This procedure makes pronation and supination impossible. Removal of the outrigger and its screw can be carried out after three to four weeks when healing of the injured structures can be assumed. The outrigger should be removed first and gentle pronation and supination performed. If there is significant pain associated with these movements, the outrigger should be replaced and left in place for at least two more weeks. Since this technique will be used in cases involving substantial injury to the wrist, the final result will be greatly influenced by the extent of the damage.

Wrist Mobilization: If controlled wrist mobilization is desired, the distal ball-joint aligned with the center of rotation of the wrist may be loosened by unlocking the cam. This will allow 40-50 degrees of flexion and extension of the wrist. **It is essential to ensure that the security collars are fully tightened and this should be checked at regular intervals.**



PRECAUTION: The surgeon must evaluate the integrity of the construct at follow-up visits.

The patient should now practice flexion and extension². Provided the fixator has been applied correctly, radial shortening and fracture fragment displacement cannot occur during wrist movement, because the rotational axis of the fixator is external to the rotational axis of the wrist. If significant pain at the fracture site is reported by the patient on mobilization, the ball-joint should be locked for another week after which a further attempt at wrist mobilization may be made.



The use of bone grafting and limited internal fixation has been discussed in the literature³. The following section contains examples of situations in which these techniques might be used. However, each case must be assessed individually by the surgeon in charge. The use of a tourniquet is strongly recommended in these cases.

HARVESTING BONE GRAFTS

The iliac crest is a suitable donor site. A small bone block (10x10x10mm) with one cortex can be taken from the inner table of the ilium through a 3cm incision. Cancellous bone should be taken in addition to this. Alternatively, a large bore bone biopsy needle can be used: this technique, which has a low associated morbidity, has been described by Saleh⁴. Other sites include the greater trochanter and the proximal tibia. The olecranon is not ideal as a donor site, since its cancellous bone has a rather coarse structure.

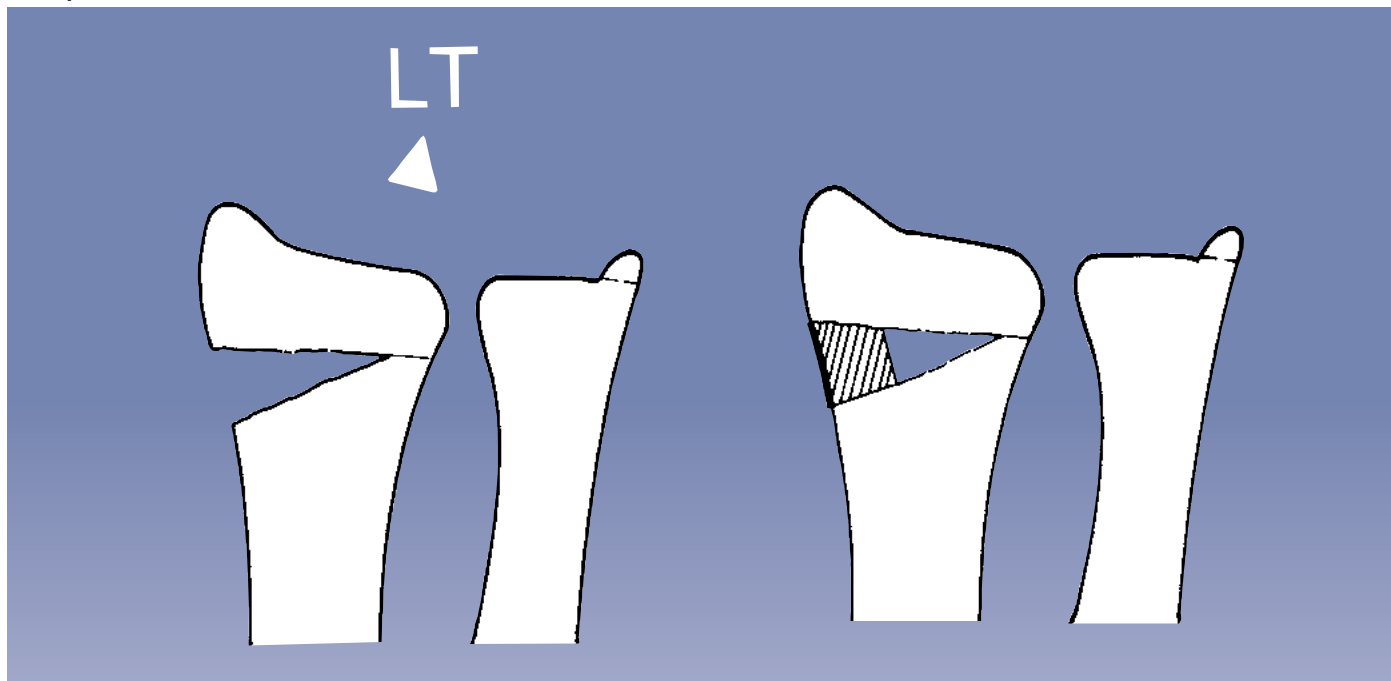
LIMITED INTERNAL FIXATION WITH THE ORTHOFIX FRAGMENT FIXATION SYSTEM

If internal fixation is indicated due to the fracture pattern, special fixation wires are available. These fixation wires have a variable thread length (see page 12) and a shoulder to maintain compression.

This system combines the simplicity of a Kirschner Wire with the secure fixation of a screw. When drilling through the fractured fragment, reduction is maintained by pushing against the fragment and slipping of the fragment avoided when the shoulder of the larger polished shaft reaches the cortex. Pre-operative measurement of the required length should be carried out on the fracture X-ray. Penetration of the opposite cortex may be necessary in osteoporotic bone, but in general is not required. It is important to use a drill with clockwise and counterclockwise rotation capability. Washers with a diameter of 4mm (W1600) are available for use in situations where there is osteoporosis or any comminution of the cortex. Examples of the use of the system are illustrated on pages 25-26.

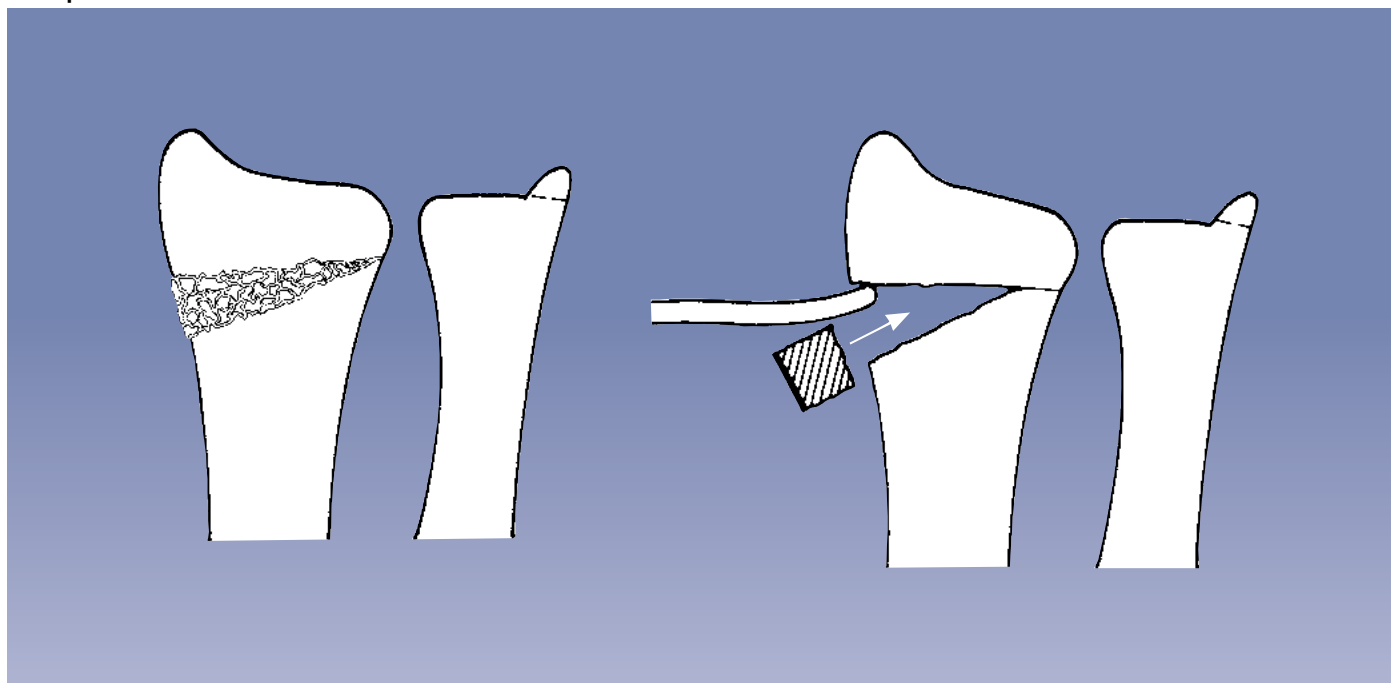
The first step consists in application of the fixator using the technique described. Manual traction and gentle manipulation with direct pressure on the radial fragments should be used in an attempt to achieve reduction. It is at this point that the need for grafting and/or fixation wires (Orthofix Fragment Fixation System) should be determined using an Image Intensifier. For wrist function, the radial length and the radial angle are very important. The dorsal angle must be checked in a lateral view and this must also be restored.

Example 1

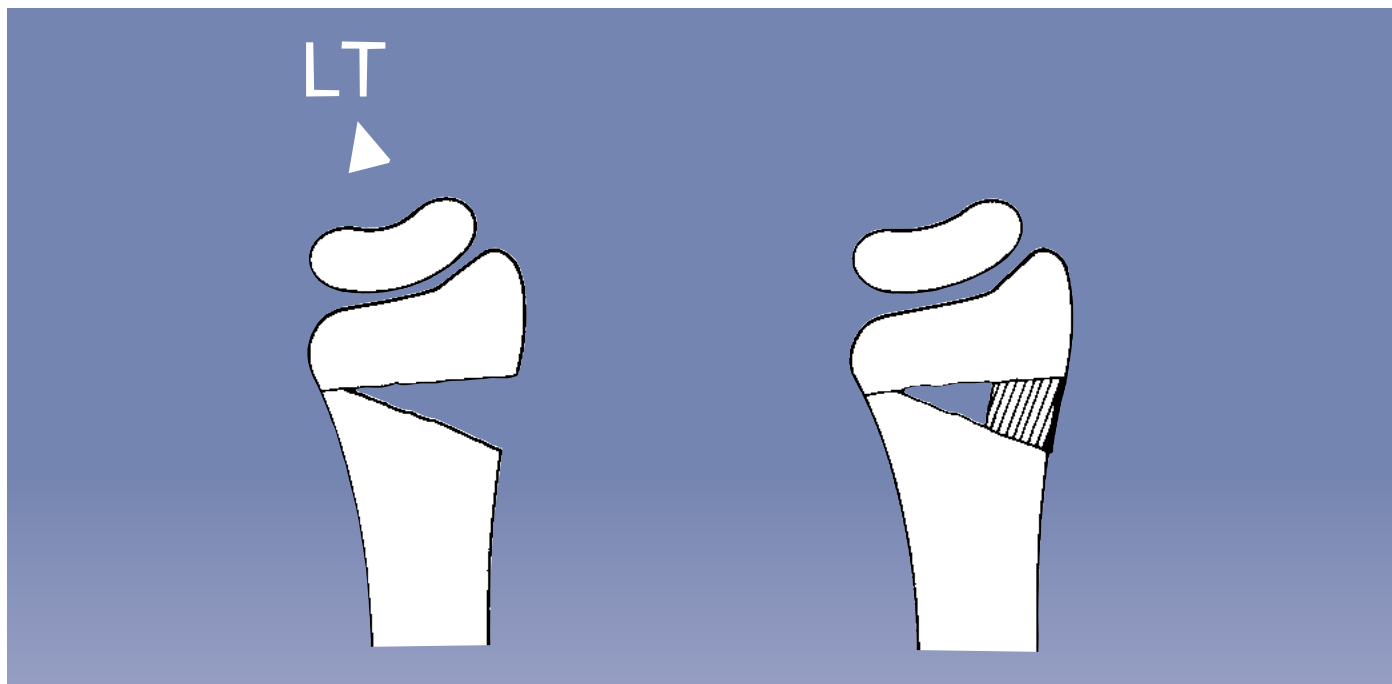


Ligamentotaxis (LT) reduces the fragment and a bone defect is visible in the AP view. A 25mm incision over the radial styloid is used to expose the defect (caution: avoid the superficial branch of the radial nerve), which is then filled by the bone block shaped to fit. The cortex of the block should be sited as shown.

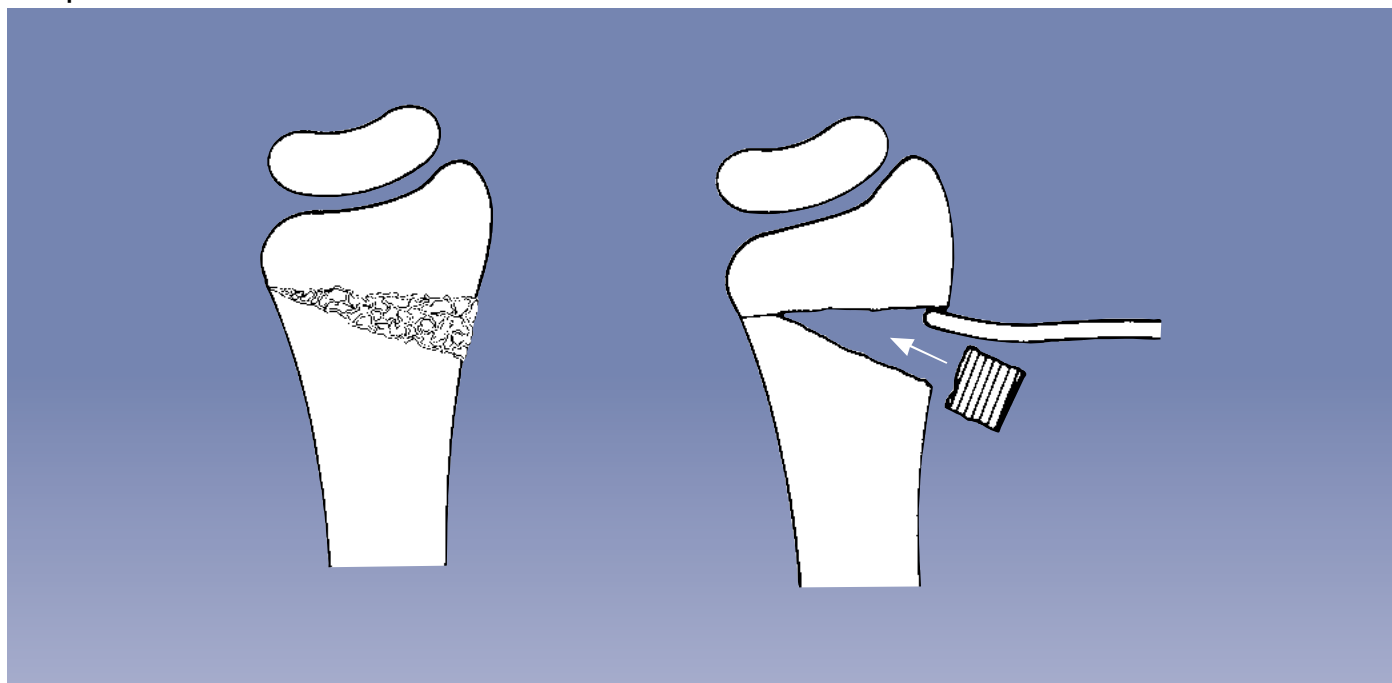
Example 2



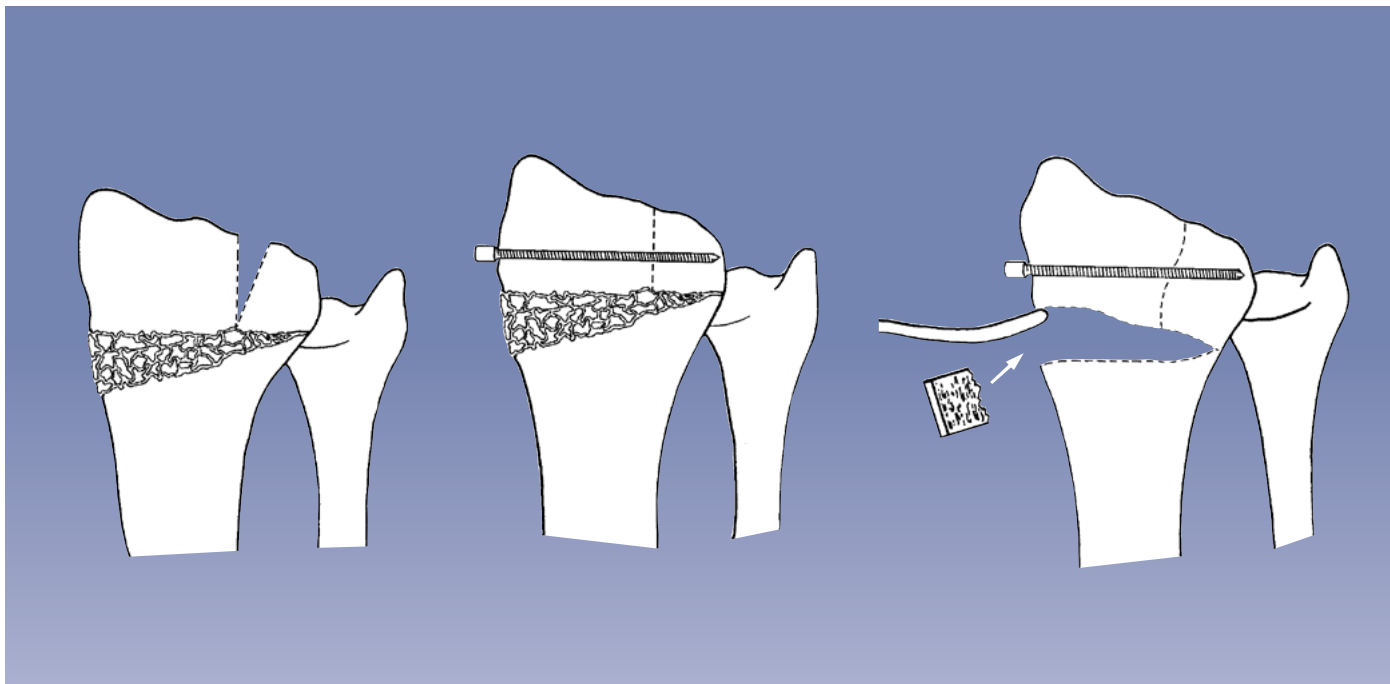
If ligamentotaxis fails to elevate the radial fragment and thereby restore the radial length, a bone elevator can be introduced through a similar incision. A defect usually results and this can be filled as shown.

Example 3

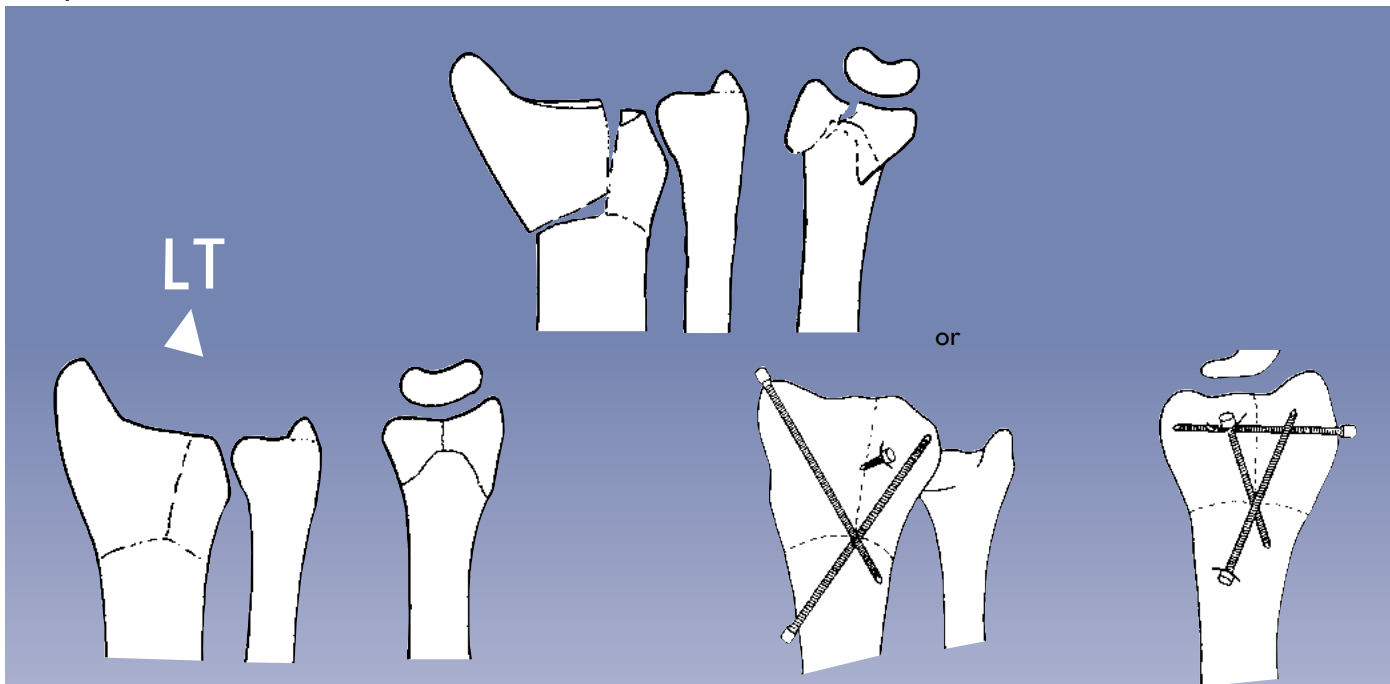
Ligamentotaxis (LT) reduces the fragment and a bone defect is visible in the lateral view. A 25mm incision is made over the dorsal aspect of the distal radius. The landmark for this is the radial insertion of the dorsal radiocarpal ligament. The extensor retinaculum must then be separated and the extensor tendons retracted. Care must be taken to avoid damage to the tendon of the extensor pollicis longus, which crosses in this region. The defect should be filled as shown. For wound closure, follow the standard techniques of hand surgery.

Example 4

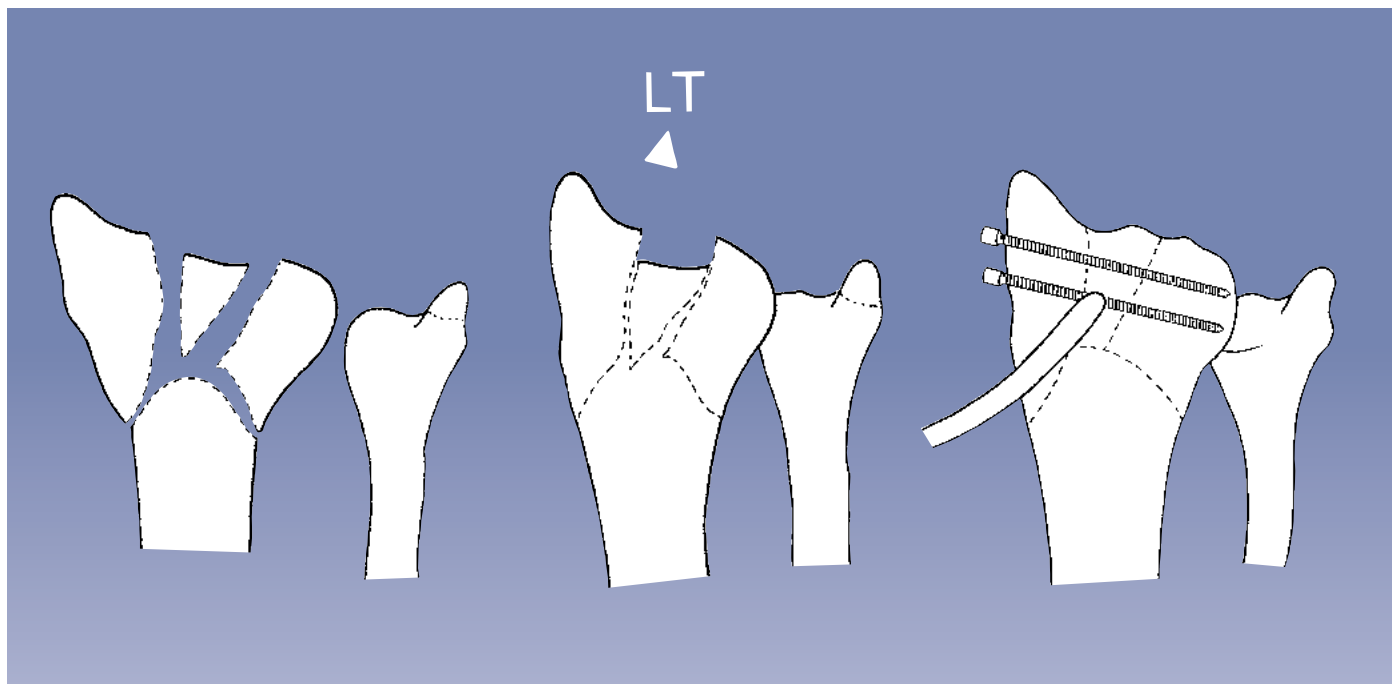
If ligamentotaxis fails to elevate the radial fragment and thereby restore the dorsal angle, a bone elevator can be introduced through a similar incision. A defect usually results and this can be filled as shown.

Example 5

If ligamentotaxis fails to reduce a fracture gap of the size indicated, the articular surface of the radius can be restored using a bone elevator. The reduction can then be maintained using one or two fixation wires (Orthofix Fragment Fixation System). If elevation of the distal radial fragment is necessary and a bone defect results, follow the method illustrated in example 1.

Example 6

If ligamentotaxis (LT) applied to this type of fracture is followed by a satisfactory result, limited internal fixation may not be necessary. If redisplacement occurs, fixation wires (Orthofix Fragment Fixation System) can be used to secure the reduction of the joint. The fracture should be neutralized by the fixator.

Example 7

If in the AP or lateral view a large depressed part of the distal radius remains unreduced, this can be elevated with a bone elevator and secured by fixation wires (Orthofix Fragment Fixation System) positioned parallel to the joint. Please consult textbooks on hand surgery for possible approaches, which will depend upon the precise position of the fragment.

BONE SCREW ANCHORAGE IN OSTEOPOROSIS

Osteoporosis particularly affects the trabecular structure of cancellous bone. The proximal metacarpal screw is placed at the junction of metaphysis and diaphysis, and the bone in this area might feel soft during drilling. If a surgeon feels that additional anchorage is required, the number of cortices engaged can be increased. This should not be achieved by drilling through the third metacarpal, but by sliding another clamp (37040) on to the short module of the fixator (37010) and adding a third screw, which is engaged in the diaphysis. Standard screws should be used with a thread diameter of 3.0-3.3mm. It is important to aim for the center of the bone to ensure maximal screw grip.



PRECAUTION: Diaphyseal bone screws and wires should always be inserted perpendicular to and in the center of the bone axis to avoid weakening it.

INDICATIONS FOR THE USE OF THE SMALLER SCREW

Screws with a thread diameter of 2.5-3.0mm, 70/20 length are now available together with a special 2.0mm drill bit and drill guide (see page 12). The shank size is the same as that of the standard screw (4.0mm). **These screws are not to be used in osteoporosis**, because the force at the bone-screw interface is increased if the screw has a smaller diameter. They are supplied for use when the metacarpal diameter is too small for the standard screws. This may be the case in populations of smaller stature and in younger patients. Even in these patients, the metaphysis will probably accommodate a standard screw and this should be used when possible. **The smaller screw should be reserved for diaphyseal fixation when the outer diameter of the bone is less than 9mm.**

It is imperative that the appropriate drill size is used for the thread diameter of the screw selected. If the 2.0mm drill bit is used instead of the 2.7mm drill bit for standard screws (3.0-3.3mm), screw insertion may cause microfractures, with early screw loosening. Alternatively, if the standard 2.7mm drill bit is used for the small (2.5-3.0mm) screws, fixation will be inadequate because the pilot hole will be too large.

To avoid the risk of this happening, the 2.0mm drill bit and drill guide, and the complementary 2.5-3.0mm screws are identified by a roughened surface and supplied in a separate kit (13555), containing:

- 4 Cortical Screws 4.0mm diameter shaft, 70/20, 2.5-3.0mm thread (35156)
- 1 Drill Bit 2.0mm diameter (13551 A)
- 1 Drill Stop 2.0mm diameter (13552)
- 1 Drill Guide 2.0mm diameter (13531)
- 1 3mm Allen Wrench (10012)

INTRODUCTION

Loss of the correct anatomy of the wrist joint after trauma has been shown to cause pain, loss of function and may lead to arthritis. The symptoms will be a particular handicap to patients who need a strong mobile wrist joint for work, sport or other daily activities, and in all situations affecting the dominant hand.

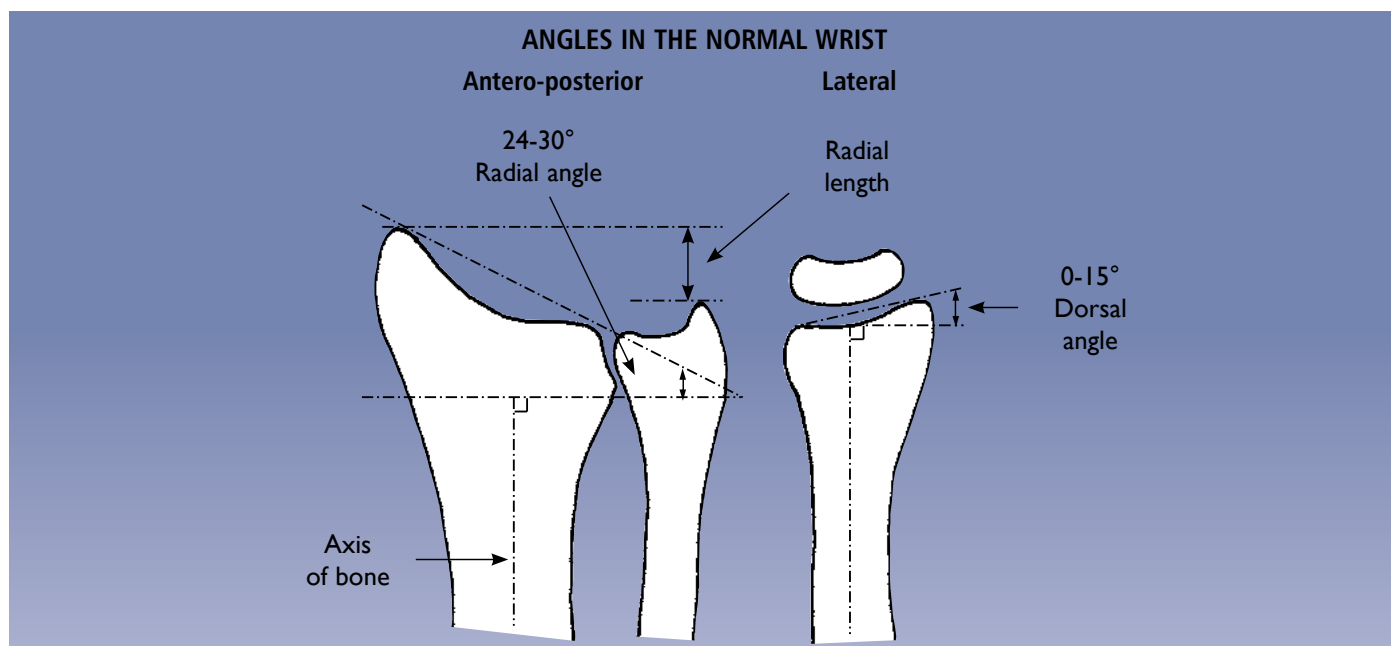
It is possible to use this fixator to correct the deformity and thereby restore normal function and prevent the development of arthritis. The aim of the treatment is to restore radial length and the angle of the radial articular surface in both planes.

The majority of cases will be post-traumatic in adults, but the technique can also be used in cases of congenital malformation or in the late results of distal radial growth plate injuries.

The best time to intervene following a fracture is about 9 to 12 months after injury. This delay will allow for full bony healing and for the quality of the bone stock to return to normal. If significant osteoporosis persists, the following procedures should be delayed until the bone stock has improved.

OBJECTIVES AND PRIORITIES

These are the correction of radial length, radial angle, radial shift and dorsal angulation. In some cases the restoration of normal or near normal anatomy may be only the first step in the treatment of a post-traumatic deformity of the wrist. Additional measures may be necessary and the standard techniques of hand surgery must be followed.



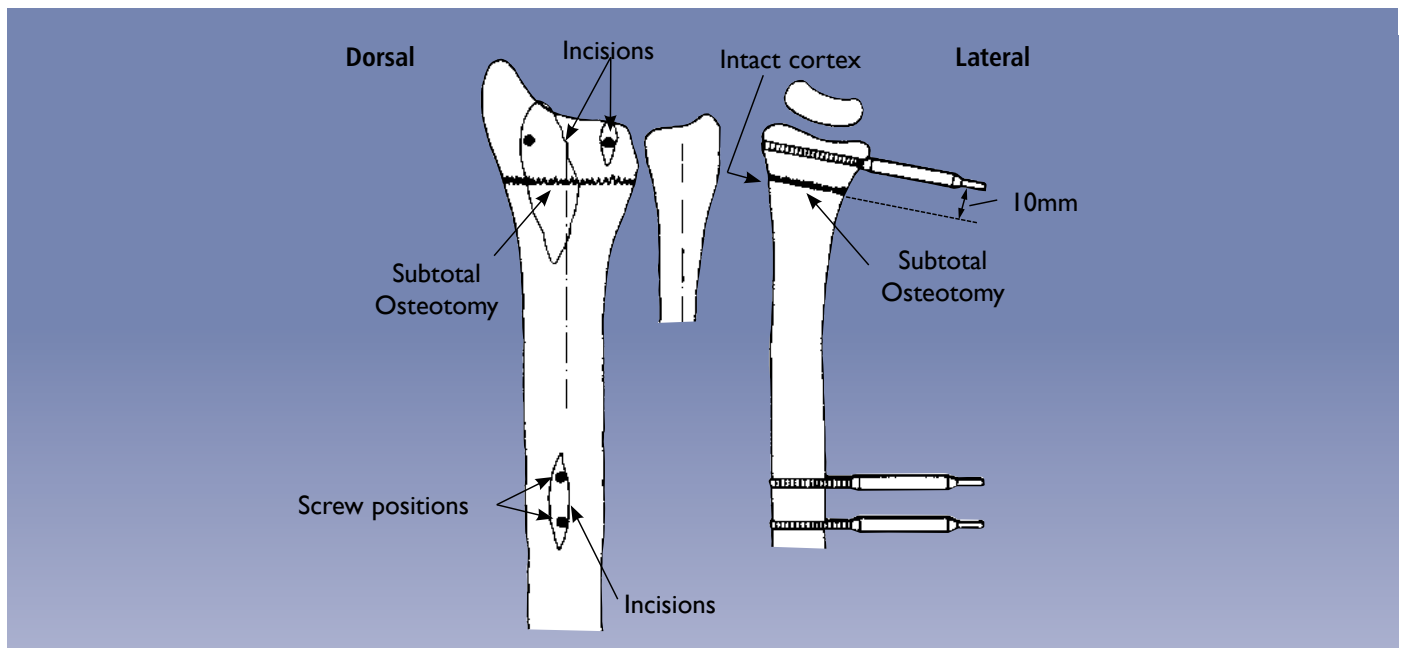
PLANNING THE OPERATION

The steps required to restore the normal anatomy should be planned carefully preoperatively. The antero-posterior and lateral views in this diagram show the normal anatomy with a radial angulation of 24-30° and a dorsal angulation of 0-15°. However, there may be considerable individual variation and where possible **it is strongly recommended that comparison is made with a radiograph of the opposite normal wrist.**

The operation will involve one or more of the following procedures:

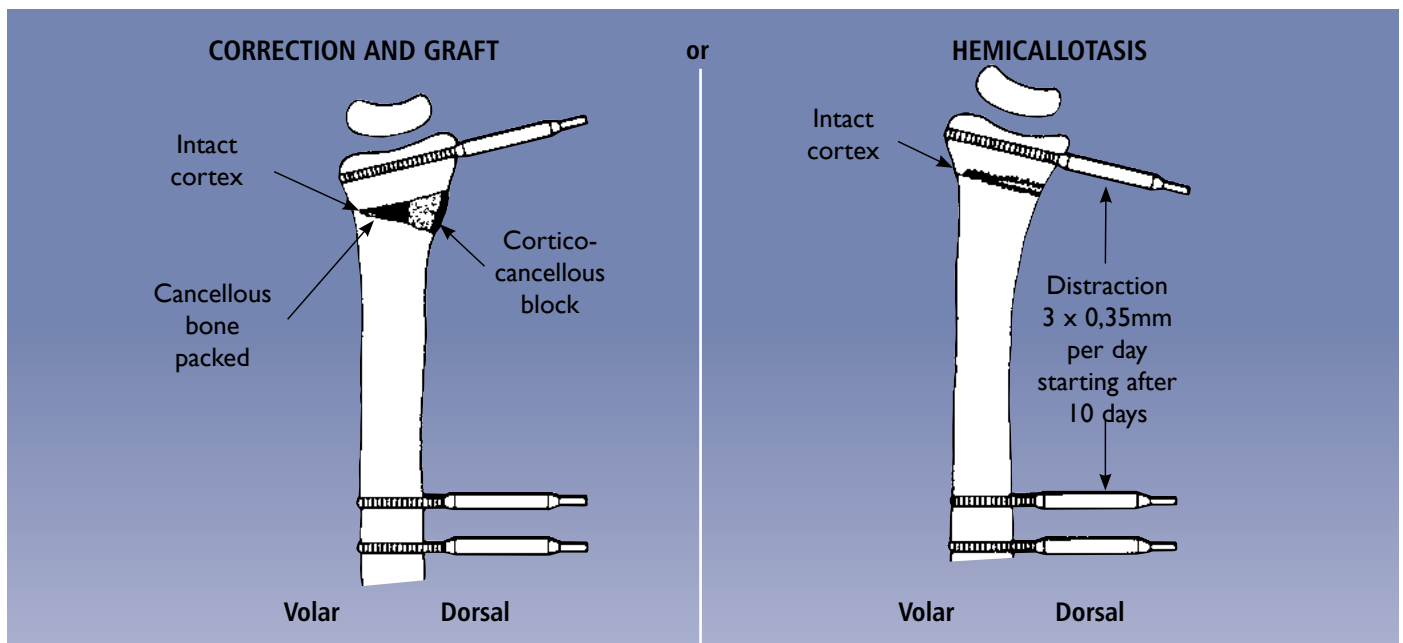
- restoration of dorsal angulation;
- restoration of radial length;
- restoration of radial angulation;
- correction of radial shift.

Correction of radial length or radial shift and any combination of deformities will require a complete osteotomy. Correction of isolated radial or dorsal angulation will require a subtotal osteotomy with the radial cortex intact on the ulnar or volar side.



LOSS OF DORSAL ANGULATION

When there is loss of dorsal angulation, the AP view is normal, but the lateral view shows the abnormal angle of the distal radial articular surface. This is the example used in the description of the operative technique (see page 31). The osteotomy is 10mm proximal to the distal screws and is partial, leaving an intact volar hinge.



CORRECTION OF DORSAL ANGULATION

This can be achieved by:

- immediate correction and graft, or
- hemicallotasis.

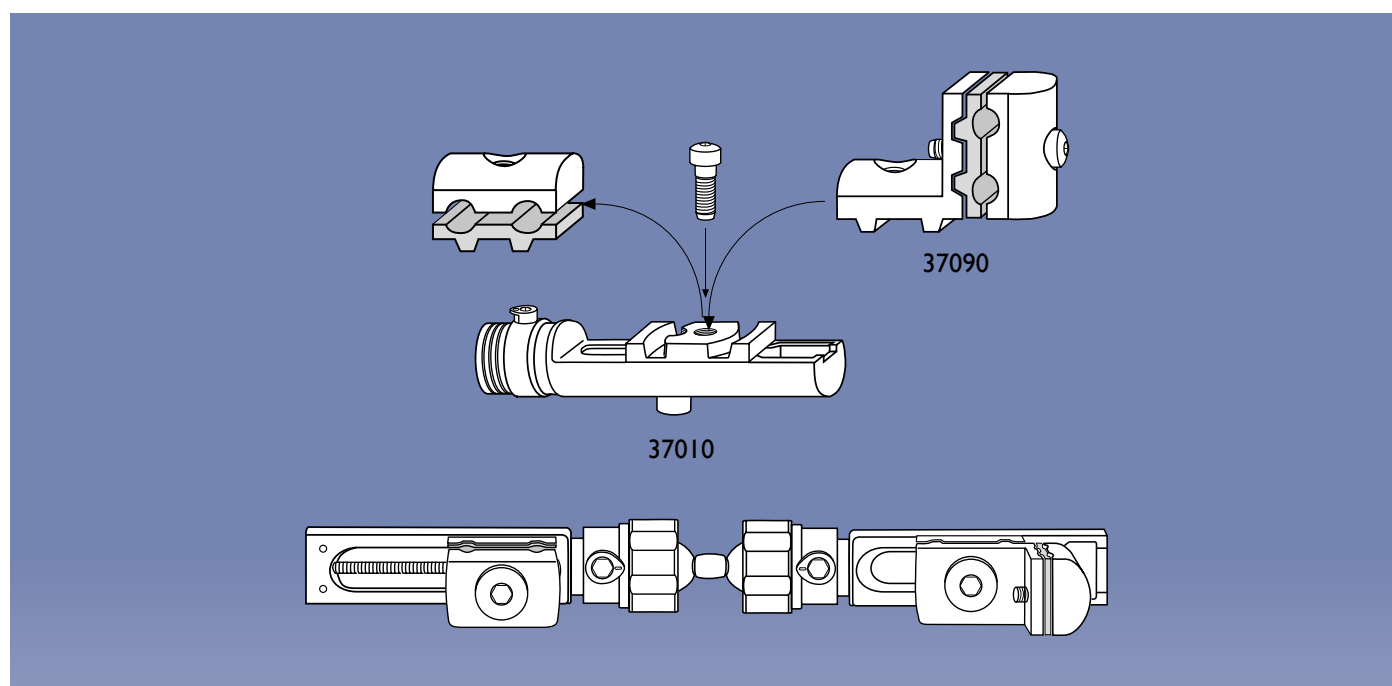
The two methods of correction depend on the preferences of the patient and the surgeon. The advantage of hemicallotasis is that no graft is required and that correction is achieved gradually rather than instantly. Also, the final position may be more accurate when it is achieved gradually with monitoring. The fixator will be in place for about three additional weeks. The detailed operative techniques for these two methods are described on pages 31 to 36. It should be remembered that hemicallotasis will correct dorsal angulation only and the presence of any other deformity requiring correction is an indication for intraoperative correction and grafting. A summary of the procedures used to correct other deformities at the wrist joint is given following the main operative technique (see pages 37, 38).

EQUIPMENT REQUIRED**Pennig Dynamic Wrist Fixator
for Extra-Articular Fractures (37002) consisting of:**

- 1 Compression-Distraction Module (37060)
- 1 Short Module with T-Clamp (37011)
- 1 Double Ball-Joint (37030)
- 2 Template/Conversion Clamps (13710)
- 2 Screw Guides/Templates with handles (13520)
- 1 Drill Guide 2.7mm diameter (13530)
- 1 Tapered Trocar (13540)
- 1 Drill Bit Kit 2.7mm diameter (13550)
- 1 T-Wrench for Clamp Screws (13570)
- 1 T-Wrench for Bone Screws (M210)
- 3 Cortical Screws 70/20,
3.0-3.3mm thread diameter (35100)
- 1 Cortical Screw 80/35,
3.0-3.3mm thread diameter (35101)
- 2 Pilot Wire Guides (13532)
for 1.5-1.6mm Kirschner Wires

ADDITIONAL INSTRUMENTATION (not provided)

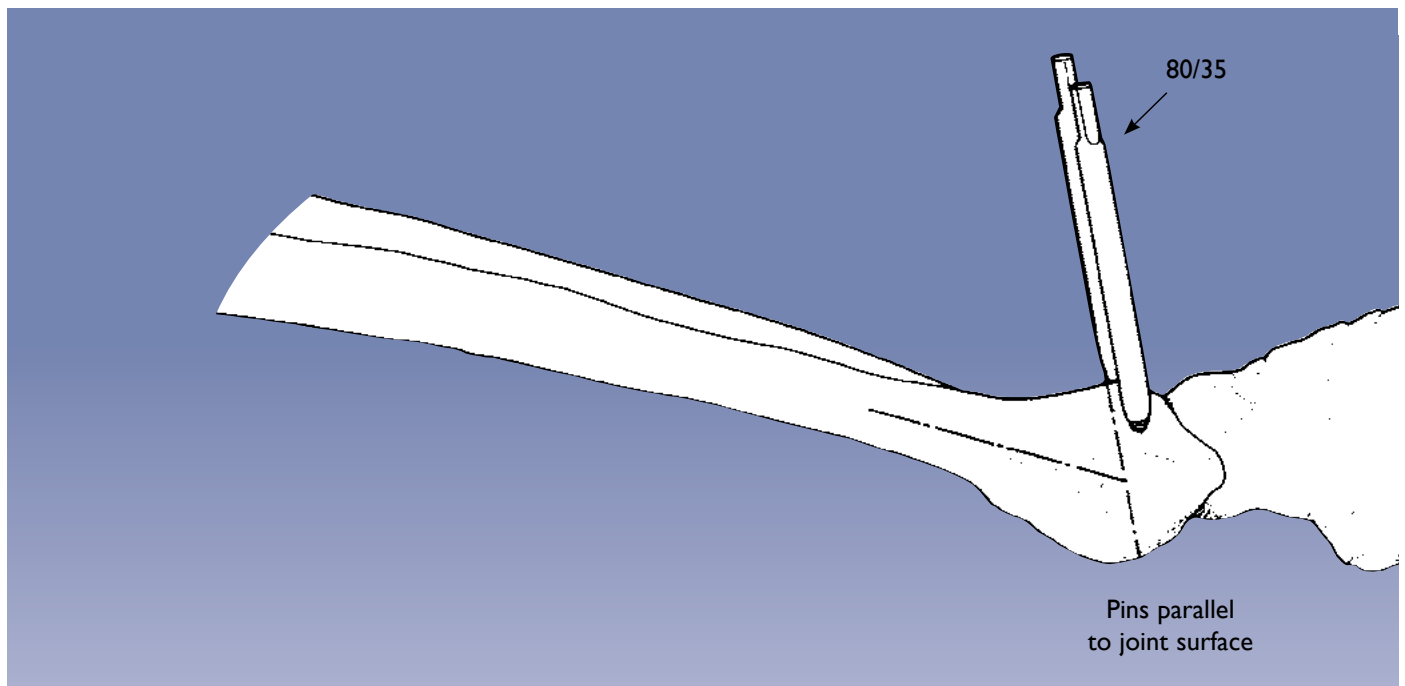
- 2 Langenbeck Retractors-Small
- Adson Forceps
- Scalpels (Nos. 11 & 15)
- Small Scissors
- Air Drill
- Osteotome set
- 2 Kirschner Wires 1.5mm or 1.6mm



If the extra-articular configuration is not available ready-assembled (37002), this may be constructed following the steps described on page 4.

The cams and bushes should be assembled exactly as on page 3. The dot on the cam must be facing the ball-joint. The collars on the ball-joints should then be screwed home fully. They cannot be screwed home fully if the cam is in any other position.

The complete fixator consists of the compression-distraction module with a straight clamp placed nearest to the ball-joint end, the double ball-joint, and a short module with a T-clamp.



OPERATIVE TECHNIQUE

Immediate Correction and Graft

Summary of Procedure:

The operation will be considered under the following headings:

Stage 1. Harvesting of Bone Graft

Stage 2. Selection and Insertion of Screws

Stage 3. Osteotomy

Stage 4. Correction and Grafting

STAGE 1: Harvesting of Bone Graft

The bone graft is taken first, before the radius is approached. The size of the graft should be estimated by pre-operative planning. It should be harvested as a cortico-cancellous block from the inner table of the ilium. A larger piece than necessary is taken together with a supply of cancellous bone chips.

STAGE 2: Selection and Insertion of Screws

80/35 or 70/20 screws are used (depending on the dimensions of the bone and the soft tissues); thread size 3.0-3.3mm; drill bit 2.7mm.

A hand table is used and a tourniquet is mandatory.

The standard procedure consists of:

(a) Insertion of the Distal Screws

It is important to expose the bone and position the screw guides under direct vision to avoid injuries to tendons and nerves.

Drilling must be performed with extreme caution in order to avoid neurovascular injury to structures on the volar side of the radius.

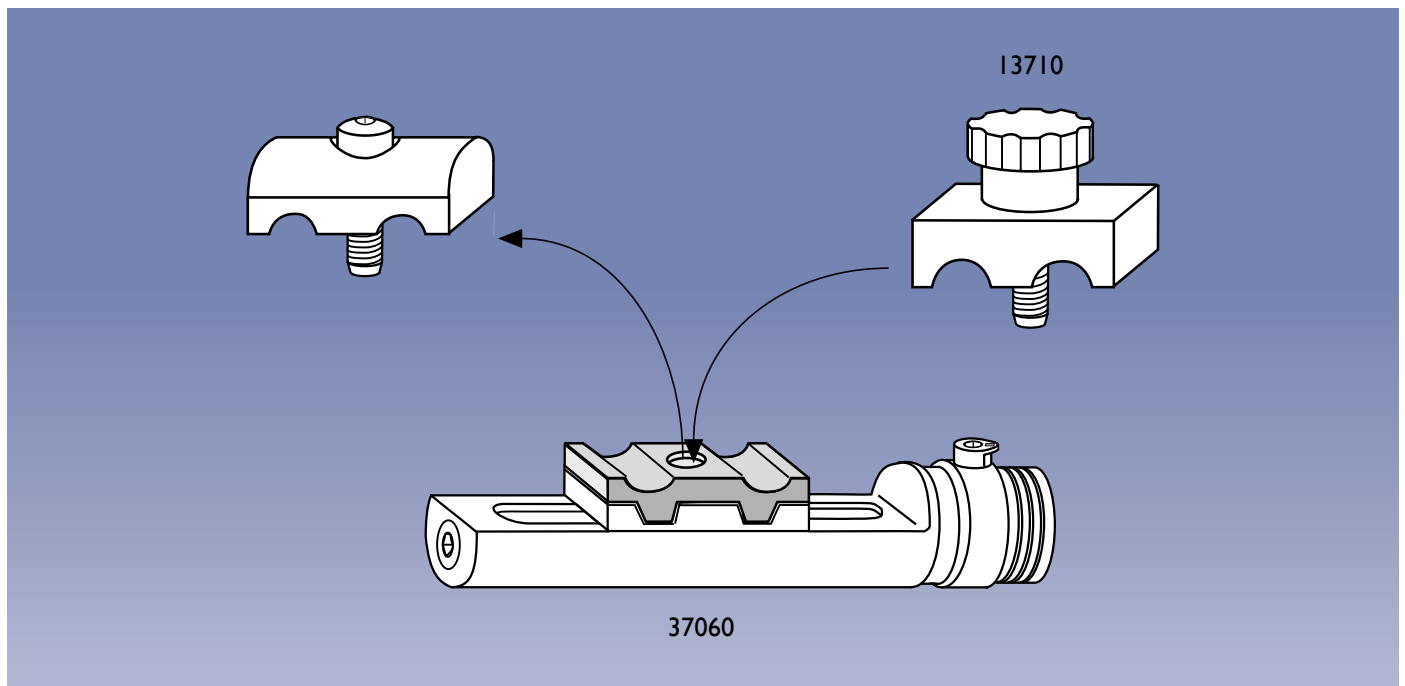


PRECAUTION: Screws and wires must be inserted with full knowledge of the safe corridors to avoid damage to the anatomical structures.

The distal screws should be inserted **strictly in the sagittal plane and parallel to the distal radial articular surface** (see fig. above).

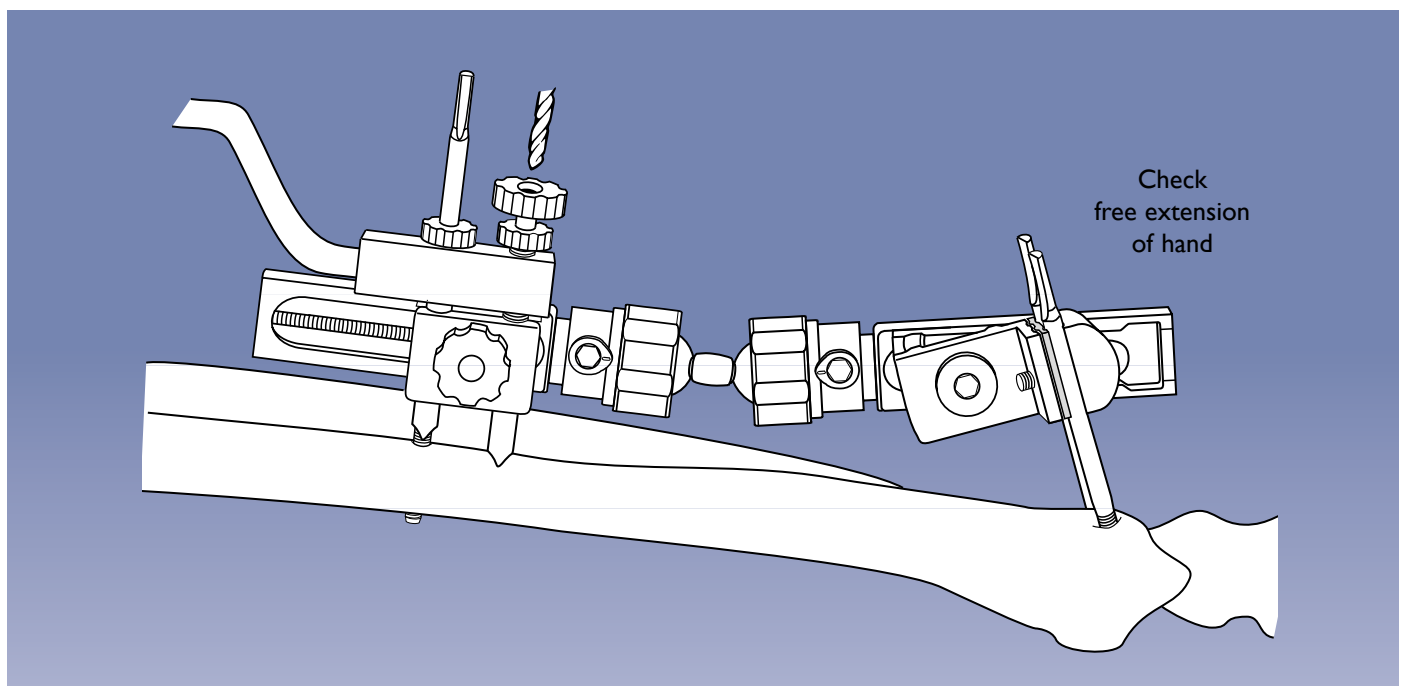
This is ensured by prior placement of pilot wires via pilot wire guides inserted into the screw guides (see pages 6-7).

A three to four centimeter incision is made from the end of the radius proximally. Further dissection should deflect the extensor digitorum tendons to the ulnar side and the extensor pollicis tendon to the radial side. The first screw is inserted within this incision into Lister's Tubercle. A second, one centimeter incision is made on the ulnar side of the radius for placement of the second distal screw.

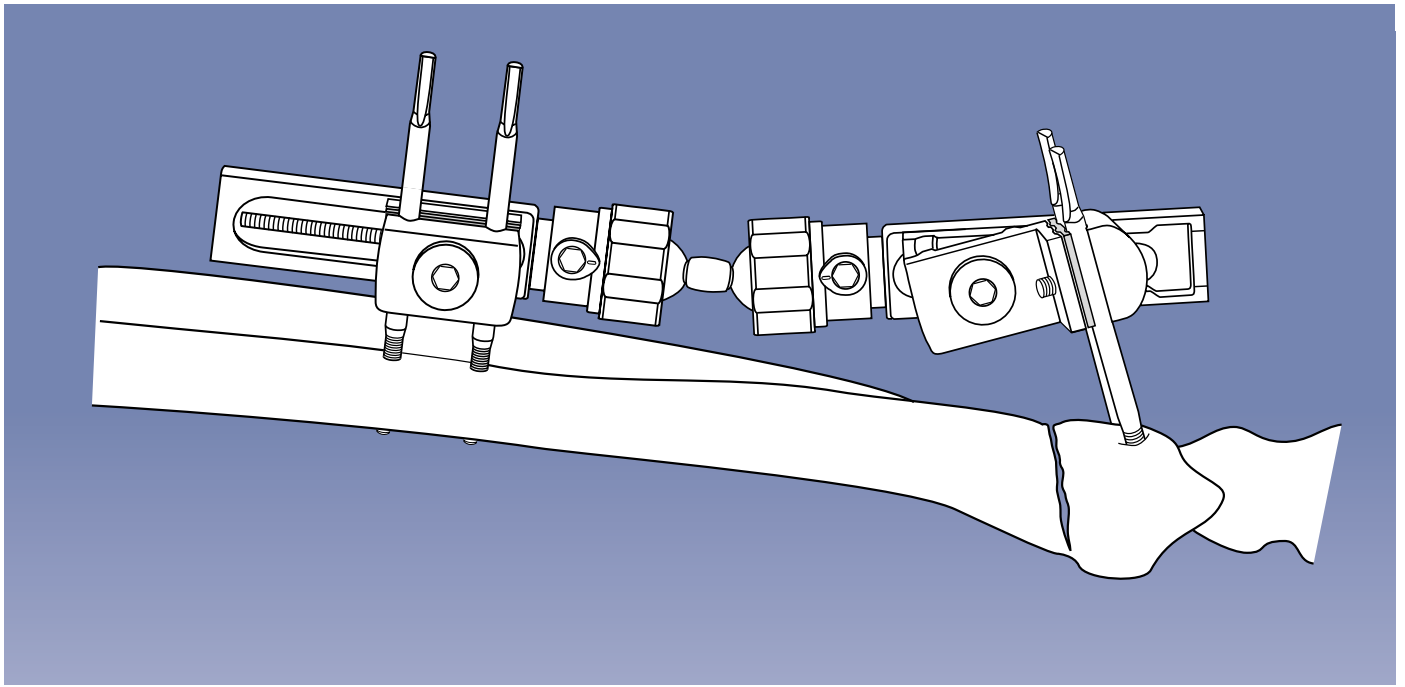


(b) Insertion of the Proximal Screws

The proximal screws are inserted with the template/conversion clamp (13710) temporarily replacing the cover of the straight clamp on the compression-distraction module, as shown in the figure above.



The fixator is now applied with the distal screws in the T-clamp. The distal clamp should be near the middle of the module, whereas the proximal clamp on the compression-distraction module is moved as close as possible to the ball-joint. The fixator is aligned so that both modules are parallel to the long axis of the radius. The incision should be near the junction of the middle and distal thirds of the bone. The position of the skin incision is marked and the fixator is swung aside to allow access. A 2.5cm incision is made and the radius exposed prior to drilling and screw insertion. The soft tissues are again carefully dissected down to the bone and protected with retractors. Special care is taken to avoid damage to the superficial branch of the radial nerve. The longer of the two screw guides is removed from the template with handle (13520) and the shorter guide is inserted into the proximal hole of the template/conversion clamp. A drill guide is inserted into the screw guide and the bone is drilled with a 2.7mm drill bit, using the drill stop when the distal cortex is reached to prevent tissue damage on the volar side. This screw is now inserted. The longer screw guide is now screwed into the template (see figure) and the second screw is inserted with the same precautions. The Image Intensifier is used to check that all four screws penetrate the distal cortex. The fixator is now removed to allow free access for the osteotomy.



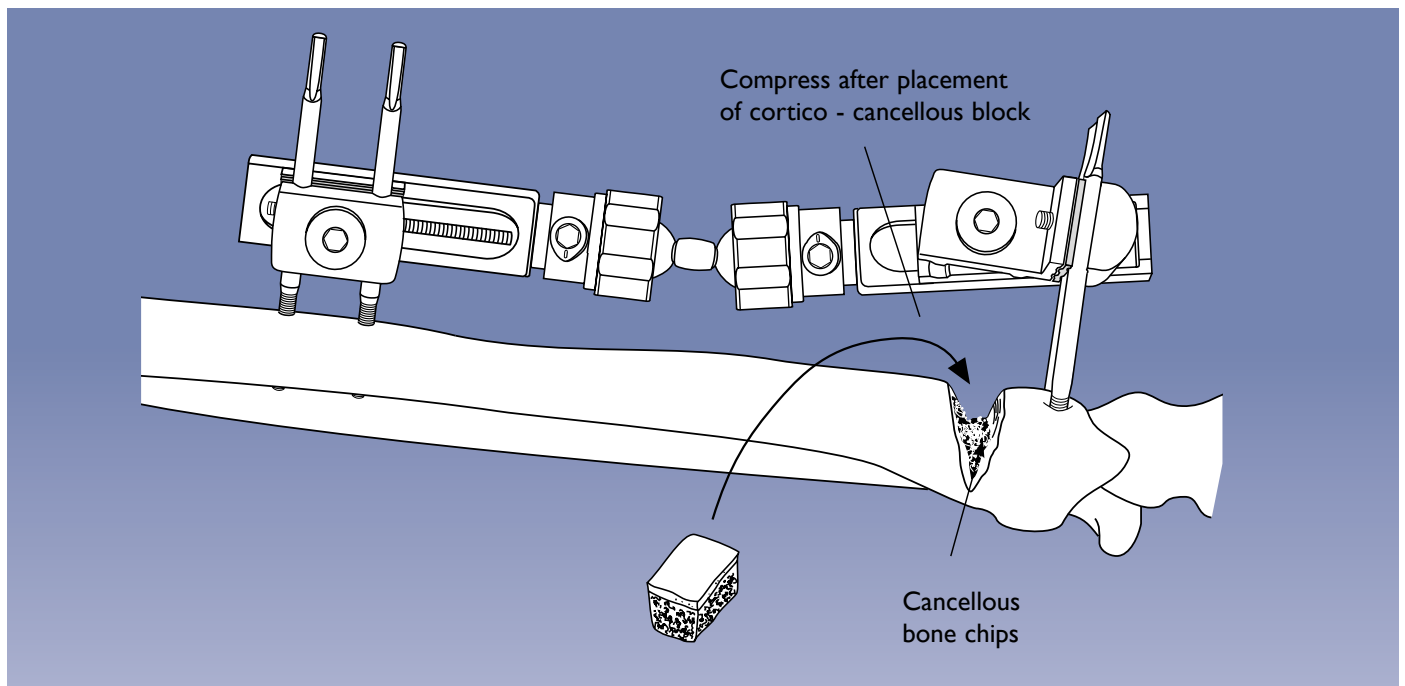
STAGE 3. Osteotomy

The type of osteotomy performed will depend upon the correction required. If correction is needed in one plane only, the osteotomy can be subtotal and the distal fragment turned into position by hinging on the opposite intact cortex. If more than one plane of correction is required, osteotomy must be complete.

The osteotomy is performed through the larger skin incision. The soft tissues are again protected and a line of drill holes made about 10mm proximal to the distal screws, using the drill stop to protect the tissues on the volar side of the radius. The osteotomy is completed with an osteotome. It is opened manually to ensure that it is adequate and the templates with handles with screw guides in place may be used to provide better leverage.

The fixator is now reapplied, ensuring that the modules are parallel to the long axis of the radius. The ball-joints and all other screws are loose at this stage.

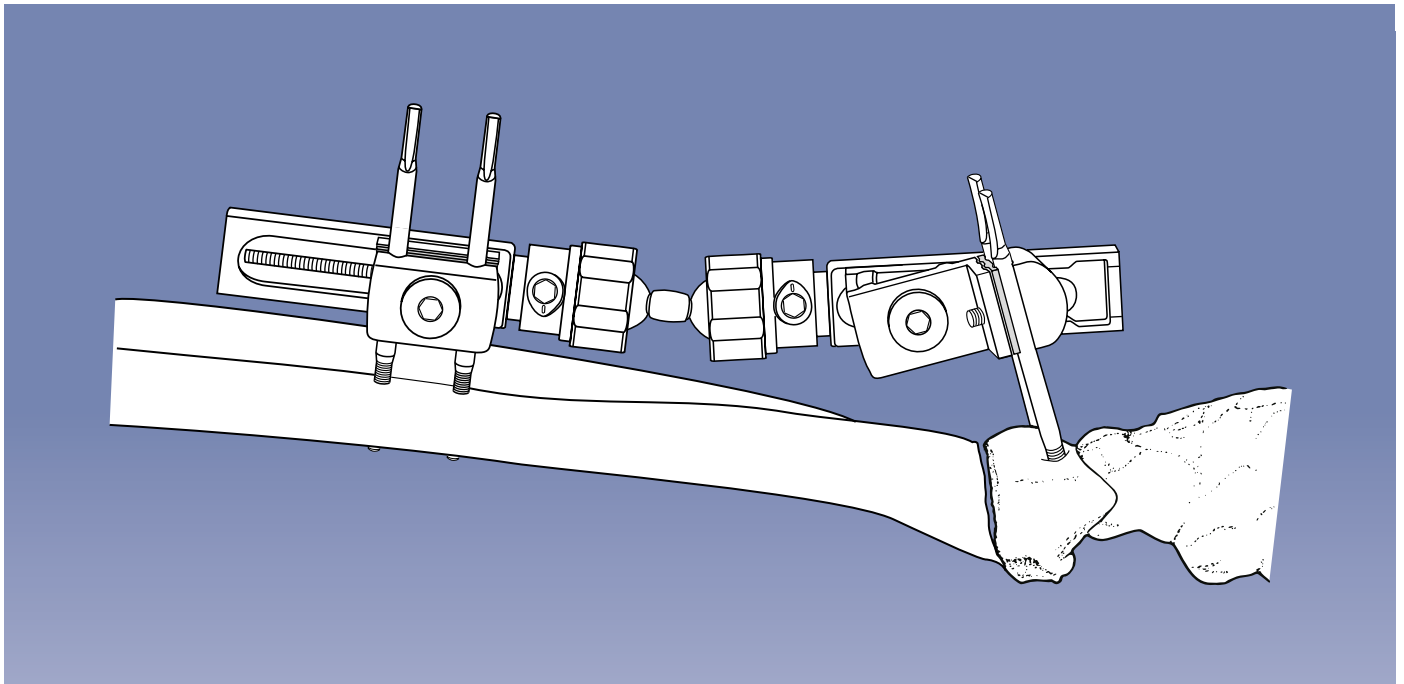
The osteotomy shown here is subtotal, allowing for correction of dorsal angulation only.



STAGE 4. Correction and Grafting

The osteotomy is now opened to correct the deformity. If the deformity has been present for some time, a smooth correction can be made with the aid of the screw guides in the templates with handles placed over the screws, with the fixator in place, to obtain gentle leverage. The distraction unit may be used to obtain final, accurate correction. A slight overcorrection is made initially to allow for insertion of the graft. The base of the osteotomy is packed with bone chips and the cortico-cancellous block, trimmed to size, is inserted in the widest part of the osteotomy. All fixator screws are now tightened, with the exception of the screw by which the T-clamp is attached to the clamp base. The graft is now gently compressed with the compression-distraction module by turning the central screw counterclockwise and the final position checked with the Image Intensifier. The T-clamp screw is now tightened.

The osteotomy wound is closed in layers and sutures are also placed in the pin insertion wounds. The fixator is left in place until union is achieved.



Alternative Procedure: Hemicallotaxis

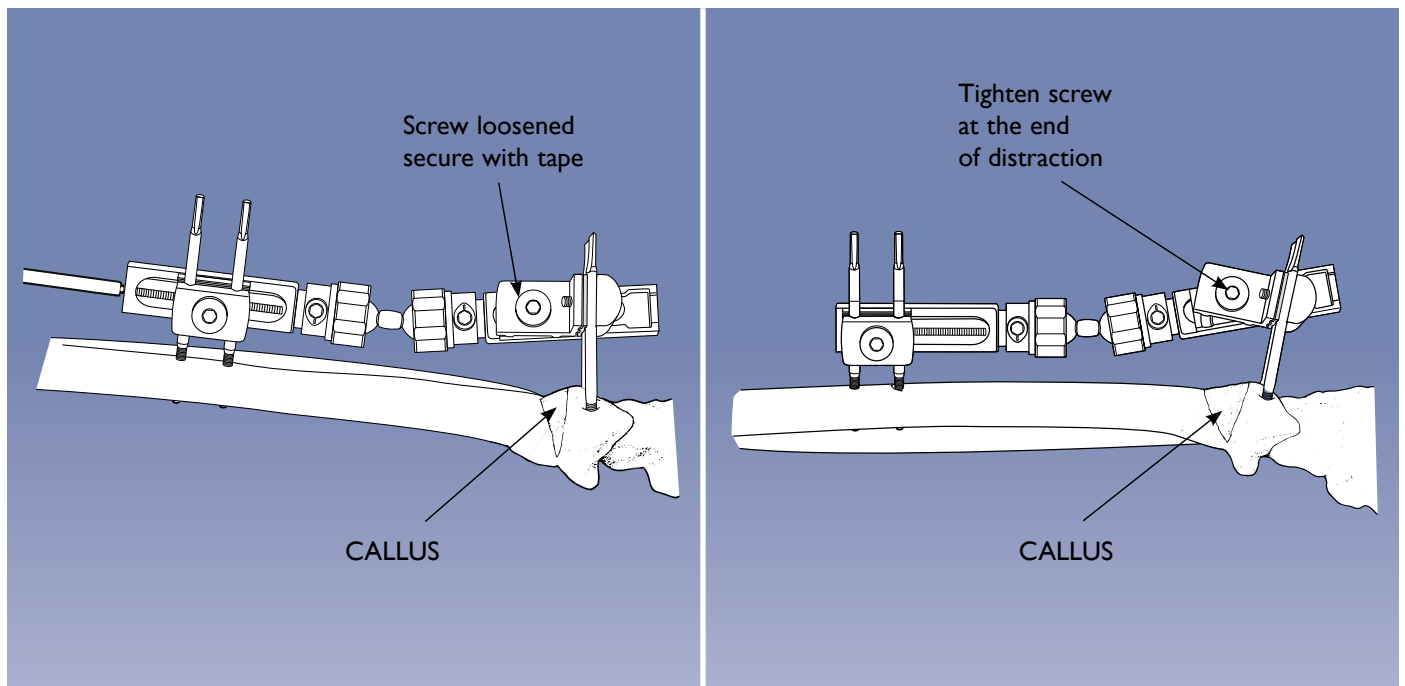
This procedure can be used for the correction of isolated dorsal angulation of the radius only, and the maximum correction possible is approximately 30 degrees.

The screws are placed as described above, with careful attention to the alignment of the fixator. In this case the screw on the base of the T-clamp must be positioned over the osteotomy, since the T-clamp will gradually rotate as the osteotomy opens (see fig. above and figs. on page 36).

The osteotomy is subtotal, through the dorsal, lateral and medial cortices, 10mm proximal to the distal screws, with careful exposure of the bone and protection of the soft tissues. The periosteum, the prime cell source for callus formation, must be preserved.

The osteotomy is carefully opened manually to confirm that it is adequate. The fixator is then applied, with the compression-distraction module proximal and the short module distal. The proximal straight clamp should be positioned at the distal end of the compression-distraction module.

The osteotomy is now closed, and the fixator screws and ball-joints all tightened. The screw by which the T-clamp is attached to the base of the distal clamp is left slightly loose, and the compression-distraction module used to check that the osteotomy will open correctly. The osteotomy is then closed completely with the compression-distraction module, and put into gentle compression by turning the central screw counterclockwise. The T-clamp screw is now tightened, and the periosteum and wounds closed with sutures.

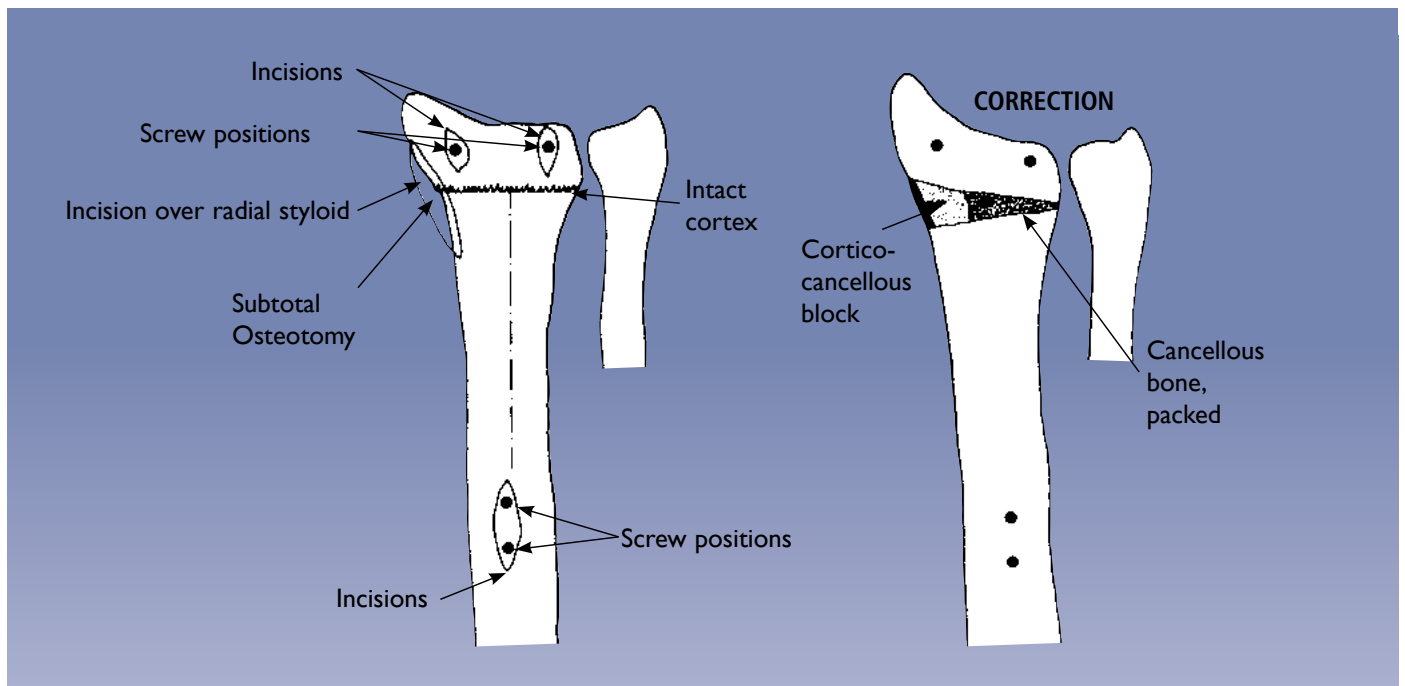


The technique of hemicallotasis is now followed as described for other sites. Initially, the osteotomy should remain undisturbed according to surgeon's evaluation. At this point the screw holding the T-clamp to the clamp base is loosened slightly. We recommend that this screw is held in place with adhesive tape to prevent further loosening. Distraction is then started at a rate of one full turn of the compression-distraction module screw clockwise per day. It is suggested that one quarter turn (= 0.25mm) is carried out every six hours, to achieve 1mm of distraction per day. The rate of distraction should be temporarily increased where rapid ossification is observed, or reduced if ossification is slow. In younger patients, the rate of distraction should be 2mm per day, half a turn (= 0.50mm) every six hours. The maximum correction possible with this method is approximately 30 degrees.



PRECAUTION: In patients undergoing callus distraction, the regenerated bone must be checked regularly and monitored radiologically.

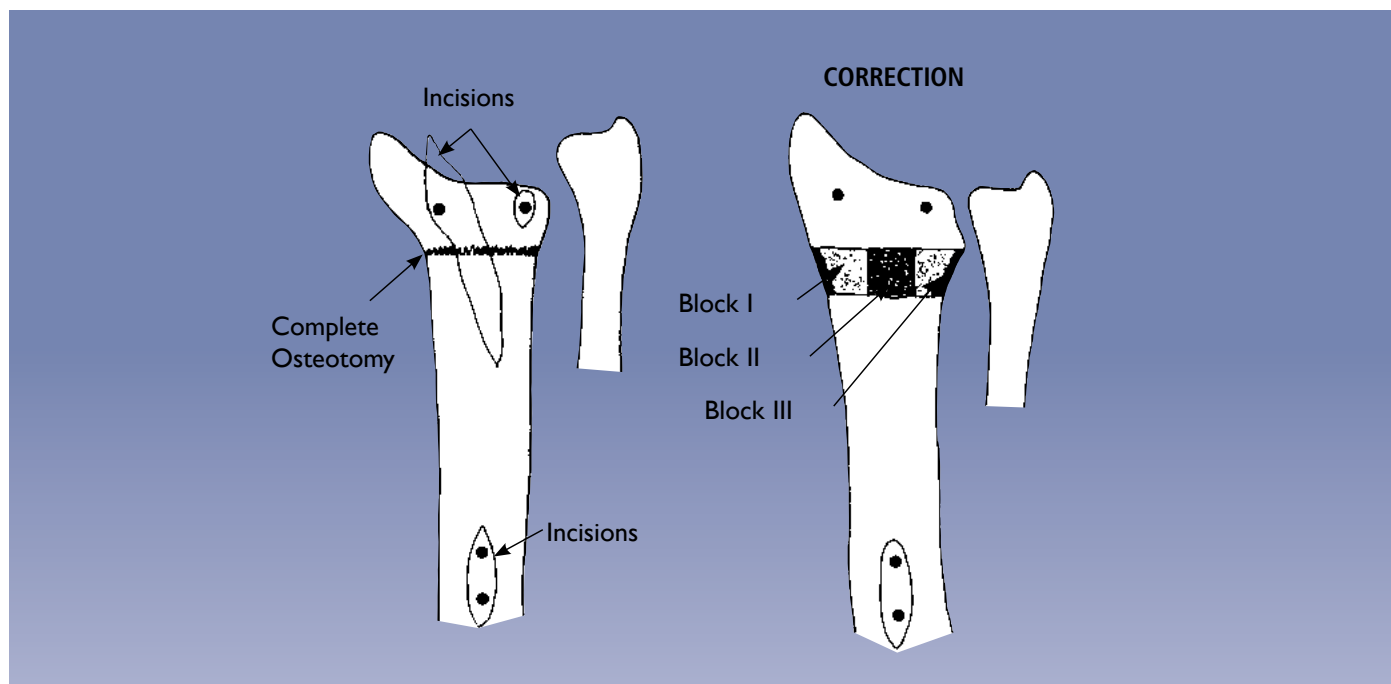
When the desired position has been achieved, the T-clamp screw is tightened, and the fixator left in position until the new bone has ossified sufficiently and the cortices have formed. This will occur after about two to four weeks. The fixator is then removed. The screws can be left in place for a few days before a final check to ensure that the radius has healed. They are then removed.



Correction of Radial Angulation

The above drawings show the position of the osteotomy for the correction of radial angulation. Note the incision over the radial styloid. The ulnar cortex of the radius is left intact and the osteotomy is opened slightly beyond the final position. The inner part of the osteotomy is packed with bone chips and a cortico-cancellous block is then inserted at the widest point.

The cortico-cancellous block is gently compressed with the compression-distraction module. The fixator is finally locked and left in place until union is complete.



Correction of Radial Length and Angulation

The osteotomy is again 10mm proximal to the distal screws and this time it is complete. It can be performed with the drill initially, using the drill stop to prevent volar soft tissue damage, and completed with an osteotome. The radial anatomy is restored with the help of the templates with handles. The fixator is locked and radial length restored by opening the compression-distraction module.

The center of the osteotomy is packed with cancellous bone chips and the distal radial fragment is supported by three cortico-cancellous bone blocks as shown:

- Block I radial side
- Block II dorsal side
- Block III ulnar side

Any remaining gaps in the bone are filled with cancellous bone chips. The osteotomy is closed into the final position, gently compressing the grafts, and the fixator locked. It is left in place until union is achieved.

Correction of Radial Shift in Association with Shortening

The same procedure can be used for the correction of radial shift with shortening. The necessary translation to correct the position can be achieved with the double ball-joints loosened, moving the distal fragment as required. Again, it is helpful to slide the screw guides in the templates with handles on to the screws, with the fixator in place, to achieve better control.

REFERENCES: DISTAL RADIAL FRACTURES

- 1) JENKINS N.H., JONES D.G., JOHNSON S.R., MINTOWT-CZYŻ WJ. *External fixation of Colles' fractures*. J. Bone Joint Surg. [Br] 1987; 69-B: 207-211.
- 2) SALTER R.B. *The biologic concept of continuous passive motion of synovial joints. The first 18 years of basic research and its clinical application*. Clin. Orthop. 1989; 242: 12-25.
- 3) LEUNG K.S., SHEN W.Y., LEUNG P.C., KINNINMOUTH A.W.G., CHANG J.C.W., CHAN G.Y.P. *Ligamentotaxis and bone grafting for comminuted fractures of the distal radius*. J. Bone Joint Surg. [Br] 1989; 71-B: 838-842.
- 4) SALEH M. *Bone Graft Harvesting: A Percutaneous Technique*. J. Bone Joint Surg. [Br] 1991; 73-B: 867-868.

BIBLIOGRAPHY: DISTAL RADIAL FRACTURES

- 1) COONEY WPIII. *External fixation of distal radius fractures*. Clin. Orthop. 1983; 180: 44-9.
- 2) DÉE W, KLEIN W, RIEGER H. *Reduction techniques in distal radius fractures*. Injury 2000; 31 Suppl. 1: 48-55.
- 3) FRYKMAN GK, TOOMA GB, BOYKO K, HENDERSON R. *Comparison of eleven external fixators for treatment of unstable wrist fractures*. J. Hand Surg. 1989; 14A: 247-254.
- 4) GAUSEPOHL T, PENNIG D, MADER K. *Principles of external fixation and supplementary techniques in distal radius*. Injury 2000; 31 Suppl. 1: 56-70.
- 5) HOWARD PW, STEWART HD, HIND RE, BURKE FD. *External fixation or plaster for severely displaced comminuted Colles' Fractures? A prospective study of anatomical and functional results*. J. Bone Joint Surg. [Br] 1989; 71-B: 68-73.
- 6) KLEIN W, DÉE W. *Erste Erfahrungen mit einem neuen Handgelenksfixateur zur Behandlung distaler Radiusfrakturen*. Handchir. Microchir. Plast. Chir. 1992; 24: 202-209.
- 7) KLEIN W, DÉE W, RIEGER H, NEUMANN HS, JOOSTEN U. *Results of transarticular fixator application in distal radius fractures*. Injury 2000; 31 Suppl. 1: 71-77.
- 8) McAULIFFE TB, HILAR KM, COATES CJ, GRANGE WJ. *Early mobilization of Colles' fractures*. J. Bone Joint Surg. [Br] 1987; 69-B: 727-729.
- 9) McQUEENMM, MACLAREN A, CHALMERS J. *The value of remanipulating Colles' fractures*. J. Bone Joint Surg. [Br] 1986; 68-B: 232-233.
- 10) McQUEENMM, CASPERS J. *Colles' fracture: Does the anatomical result affect the final function?* J. Bone Joint Surg. [Br] 1988; 70-B: 649-651.
- 11) NOORDEEN MHH, LAVY GB, WOODWARDS RT. *Remanipulation or external fixation after slipped Colles' fractures? An anatomical study*. Injury 1992; 23 (5): 303-304.
- 12) PENNIG D. *The use of external fixation in radial fractures*. J. Japanese Orthop. Assoc. 1991; 65: 279.
- 13) PENNIG D, GAUSEPOHL T. *External fixation in fractures of the distal radius using a lightweight Dynamic Axial Fixator*. Supplement to International Journal of Orthopaedic Trauma 1993; 3 (3): 29-32.
- 14) PENNIG D. *Dynamic External Fixation of distal radius fractures*. Hand Clinics 1993; 9 (4): 587-602.
- 15) PENNIG D, GAUSEPOHL T, LUKOSCH R. *Dynamic external stabilisation in the management of distal radius fractures*. In: Cziffer E (ed.). Minifixation. External fixation of small bones. Literatura Medica, Budapest 1994; 151-160.
- 16) PENNIG D, GAUSEPOHL T, LUKOSCH R. *The Fragment Fixation System for small fragment stabilisation in hand surgery*. Handchir. Mikrochir. Plast. Chir., 1994; 26: 270-273.
- 17) PENNIG D, GAUSEPOHL T. *Extraarticular and transarticular external fixation with early motion in distal radius fractures and malunions*. Journal of Orthopaedic Surgical Techniques, 1995; 9 (3): 51-65.
- 18) PENNIG D, GAUSEPOHL T. *External fixation of the wrist*. Injury, 1996; 27 (1): 1-15.
- 19) SCHUIND F, DONKERWOLCKE M, RASQUIN C, BURNY F. *External fixation of fractures of the distal radius: a study of 225 cases*. J. Hand Surg. 1989; 14A: 404-407.
- 20) SEITZ WH, PUTNAM MD, DICK HM. *Limited open surgical approach for external fixation of distal radius fractures*. J. Hand Surg. 1990; 15A: 288-293.
- 21) VIDAL J, BUSCAYRET C, PARAN M, MELKA J. *Ligamentotaxis*. In: Mears DC. External skeletal fixation. Baltimore: William & Wilkins 1983; 493-496.

BIBLIOGRAPHY: CORRECTION OF WRIST DEFORMITIES/THE HEMICALLOTASIS TECHNIQUE

- 1) DE BASTIANI G, RENZI-BRIVIO L, ALDEGHERI R. *Chondrodiasis and Callotasis*. In: Coombs R, Green S, Sarmiento A: External Fixation and Functional Bracing. London, Orthotext, 1989: 321-327.
- 2) FERNANDEZ DL. *Correction of post-traumatic wrist deformity by osteotomy, bone grafting and internal fixation*. J. Bone Joint Surg. 1982; 64-A: 1164-1178.
- 3) JUPITER JB. *Fractures of the distal end of the radius*. J. Bone Joint Surg. 1991; 73-A: 461-469.
- 4) LANZ U. *Korrekturosteotomie nach distalen Radiusfrakturen, Technik und Ergebnisse*. In: Buck-Gramcko, Nigst H: Fracturen am distalen Radiusende Hippokrates 1987, Stuttgart, 69-77.
- 5) MacEACHERN G, FOWLER J, GIE GA. *Upper tibial osteotomy*. In: Coombs R, Green S, Sarmiento A: External Fixation and Functional Bracing. London, Orthotext, 1989: 203-206.
- 6) MÜLLER-FÄRBER J, GRIEBEL W. *Der sekundäre Korrekturingriff am distalen Radius bei posttraumatischer Fehlstellung*. Unfallheilkunde 1979; 82: 23-28.
- 7) OVERGARD S, SOLLEGARD S. *Osteoarthritis after Colles' fracture*. Orthopaedics 1989; 12: 413-416.
- 8) PENNIG D, BARANOWSKI D. *Genu recurvatum due to partial growth arrest of the proximal tibial epiphysis: correction by callus distraction*. Arch. Orthop. Traum. Surg. 1989; 108: 119-121.
- 9) PENNIG D, GAUSEPOHL T, MADER K. *Corrective osteotomies in malunited distal radius fractures: external fixation as one stage and hemicallotasis procedures*. Injury 2000; 31 Suppl. 1: 78-91.
- 10) SMAILL GB. *Long term follow up of Colles' fractures*. J. Bone Joint Surg. [Br] 1965; 47-B: 80-85.


Electronic Instructions for use available at the website
<http://ifu.orthofix.it>

Electronic Instructions for use - Minimum requirements for consultation:

- Internet connection (56 Kbit/s)
- Device capable to visualize PDF (ISO/IEC 32000-1) files
- Disk space: 50 Mbytes

Free paper copy can be requested from customer service
(delivery within 7 days):
tel +39 045 6719301, fax +39 045 6719370,
e-mail: customerservice@orthofix.it

Distributed by:



Manufactured by:
ORTHOFIX Srl
Via Delle Nazioni 9, 37012 Bussolengo (Verona), Italy
Telephone +39 045 6719000, Fax +39 045 6719380



Caution: Federal law (USA) restricts this device to sale by or on the order of a physician. Proper surgical procedure is the responsibility of the medical professional. Operative techniques are furnished as an informative guideline. Each surgeon must evaluate the appropriateness of a technique based on his or her personal medical credentials and experience. Please refer to the "Instructions for Use" supplied with the product for specific information on indications for use, contraindications, warnings, precautions, adverse reactions and sterilization.